



Reconstruction with Scapular Endoprosthesis Provides Superior Results after Total Scapular Resection: Surgical Technique and Comparison to Patients Without Endoprosthetic Reconstruction

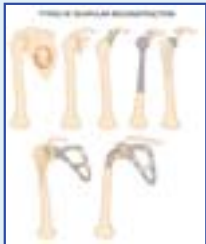Felasfa M. Wodajo, MD¹ • Jacob Bickels, MD² • James C. Wittig, MD¹ • Kristen Kellar-Graney, BS¹ • Yehuda Kollender, MD² • Isaac Meller, MD² • Martin M. Malawer, MD¹

¹Washington Cancer Institute, Washington DC • ²Tel-Aviv Sourasky Medical Center, Tel-Aviv, Israel

INTRODUCTION:

The Tikhoff-Linberg procedure, first described in 1914, involved removal of the scapula and portions of the clavicle and humerus for tumors of the scapula. Until recently, however, reconstruction of the shoulder girdle was performed simply with static suspension of the humerus from the clavicle. While this preserved hand and elbow motion, shoulder function was severely compromised.

In this report, the authors compare their experience with suspension of the humeral head from the clavicle after total scapular resection with endoprosthetic scapular reconstruction.



Methods of reconstruction after scapular resection

PATIENTS:

Between 1979 and 1997, the authors treated 23 patients with scapular tumors (14 bone, 9 soft tissue) that required total scapular resection. Resection included total scapulectomy in 12 patients and en-bloc resection of the scapula and humeral head in 11 patients. Seven of these patients underwent endoprosthetic reconstruction. Of the remaining 16 patients, four had prosthetic humeral heads suspended from the clavicle and the other 12 had suspension of the native humeral head. All patients were followed for a minimum of 2 years; follow-up included physical examination and radiological evaluation according to the American Musculoskeletal Tumor Society system.

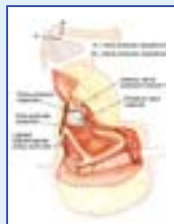SURGICAL TECHNIQUES:

Patient selection is important to ensure that the appropriate peri-scapular muscles (trapezius, deltoid, rhomboids, latissimus dorsi) are free of tumor and thus endoprosthetic reconstruction is feasible. Tumors originating in the scapula, even if involving the glenohumeral joint, usually remain contained by the adjacent supraspinatus, infraspinatus and subscapularis muscles. However, the final decision to proceed with endoprosthetic reconstruction is made at the time of surgery.

Humeral head suspension from the clavicle (without scapular endoprosthesis) has been described previously.

RESECTION

Scapular resection is performed using a posterior approach unless there is an anterior tumor component necessitating an anterior incision and exploration of the axillary artery and brachial plexus. The trapezius and deltoid are first divided at their scapular spine and acromion attachments after which the remaining periscapular muscles, including the rhomboids, teres major, minor, serratus anterior and levator scapulae are divided 1 - 2 cm from the scapula. The scapular insertion of the latissimus dorsi is detached.

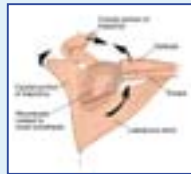

Most high-grade tumors of the scapula are resected via an extra-articular osteotomy of the proximal humerus distal to the rotator cuff insertion and proximal to the deltoid insertion.

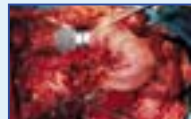RECONSTRUCTION



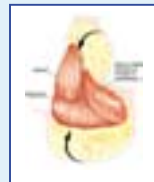The prosthesis is smaller than a natural scapula to simplify soft-tissue reconstruction and multiply fenestrated to allow for myodesis.



The prosthesis is placed on the serratus anterior and attached to and covered by the rhomboids, trapezius and latissimus dorsi. The latissimus dorsi is mobilized superiorly to cover the inferior 2/3 of the prosthesis and provide protection to the prosthesis from subcutaneous placement.



A curved humeral head prosthesis is cemented into the proximal humerus and connected to the scapular prosthesis by an artificial gleno-humeral joint created using a Gore-tex™ sleeve.



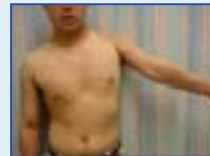The deltoid and trapezius muscles are tenodesed to each other to recreate the abduction moment

RESULTS:


There were no deep wound infections, prosthetic failures, or secondary amputations. Elbow range-of-motion and hand dexterity were similar in the two groups of patients.



Post-operative radiograph with scapular endoprosthesis.



Compared with patients who underwent humeral suspension, those who had scapular endoprosthesis had better active abduction (60 - 90 deg. vs. 10 - 20 deg.) of the shoulder joint.



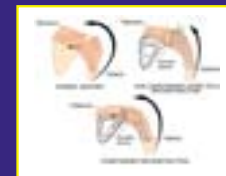Overall, 6 patients who had scapular prosthesis (86%) and 10 patients who had humeral suspension (62%) had a good-to-excellent functional outcome.

CONCLUSIONS

- The method of reconstruction described here has not been associated with any prosthetic or wound failures.
- Reattachment of the rhomboids, levator scapulae and serratus anterior effectively stabilizes the scapula against the chest wall and allows for forceful lifting and pressing use of the upper extremity.
- Preservation of the the trapezius and deltoid muscles allows for significantly improved active abduction.
- The authors recommend endoprosthetic reconstruction of the scapula after total scapular resection, instead of humeral head suspension, whenever preservation of the periscapular musculature is feasible. This is associated with better functional and cosmetic outcome when compared to simple humeral head suspension from the clavicle.



We currently employ a "constrained" (rotator cuff substituting) scapular prosthesis which has a snap-fit mechanism between the humeral and scapular components.



The new "constrained" scapular prosthesis passively recreates the stabilizing function of the rotator cuff.



Patient 9 months after constrained scapular endoprosthesis reconstruction.



Our initial results with this prosthesis are promising and may eventually surpass results presented here.