

# Low Complication Rate with Limb-Sparing Resection and Endoprosthetic Reconstruction: Survival Analysis of 251 Patients and Analysis of 20-Year Experience

Felasfa M. Wodajo, MD<sup>1</sup>; James W. Wittig, MD<sup>2</sup>; Kristen K. Graney, BS<sup>1</sup>; Jacob Bickels, MD<sup>3</sup>; Robert M. Henshaw, MD<sup>1</sup>; Martin M. Malawer, MD<sup>1</sup>

<sup>1</sup>Orthopedic Oncology, Washington Cancer Institute, Washington DC; <sup>2</sup> Dept. Orthopedics, NYU Bellevue Medical Center, New York, NY; <sup>3</sup> Tel-Aviv Sourasky Medical Center, Tel- Aviv, Israel

## INTRODUCTION

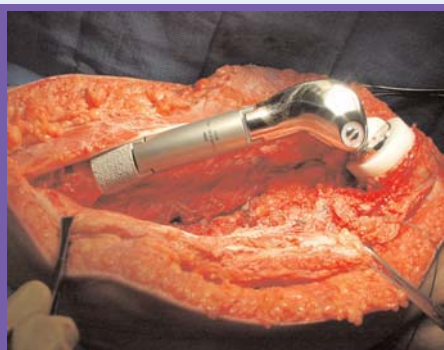
The concept of limb-sparing surgery, or limb salvage, has gradually evolved over the past 25 years. Prior to this, the basic principles of surgical oncology for the extremities consisted solely of determining the correct level at which to perform an amputation. The senior author (MM) was among the first surgeons to adopt the use of metallic segmental endoprostheses for the routine reconstruction of skeletal defects following sarcoma resections. This review summarizes the short and long term results of endoprosthetic reconstruction at multiple anatomical locations by a single surgical team.



The size of a modular prosthesis can be determined at the time of surgery and allows for maximum flexibility for the surgeon

## MATERIALS AND METHODS

Hospital and surgeon's records of all patients who underwent custom or modular endoprosthetic reconstructions performed by the senior authors since 1980 were reviewed.



A modular prosthesis inserted into the distal femur, before wound closure

For patients not having a record of visits within the last 12 months, efforts were made to contact the patients by phone or to retrieve doctors' records if patients had moved and were followed by other physicians. The majority of the reconstruction procedures were performed by the senior

author (MM) utilizing consistent surgical techniques that have been detailed elsewhere<sup>1-3</sup>. The Howmedica (Rutherford, NJ) Modular Replacement System ("MRS") was used exclusively for all non-custom endoprostheses. Almost all patients who underwent reconstruction after 1988 received modular prostheses. Patients who underwent hip hemiarthroplasties and patients who underwent reconstruction with "saddle" prostheses for periacetabular tumors are not included.

Prosthetic failure is defined as the removal of a fixed com-

ponent; i.e. the removal of a cemented stem or cemented polyethylene tray. Patients who underwent amputation for local tumor recurrence are not considered to have prosthetic failure.

Complications are classified among the following categories:

- Prosthesis*: mechanical failure of the implant or its fixation, including breakage or loosening
- Soft-tissue, superficial*: i.e. flap necrosis
- Soft-tissue, deep*: extensor mechanism failure or "pseudomeniscus" formation, etc.
- Infection*: deep infection
- Dislocation*
- Other*

## RESULTS

Limb salvage rate: 218 of 239 (91.2%)

Complications: 91 of 239 patients (38%)

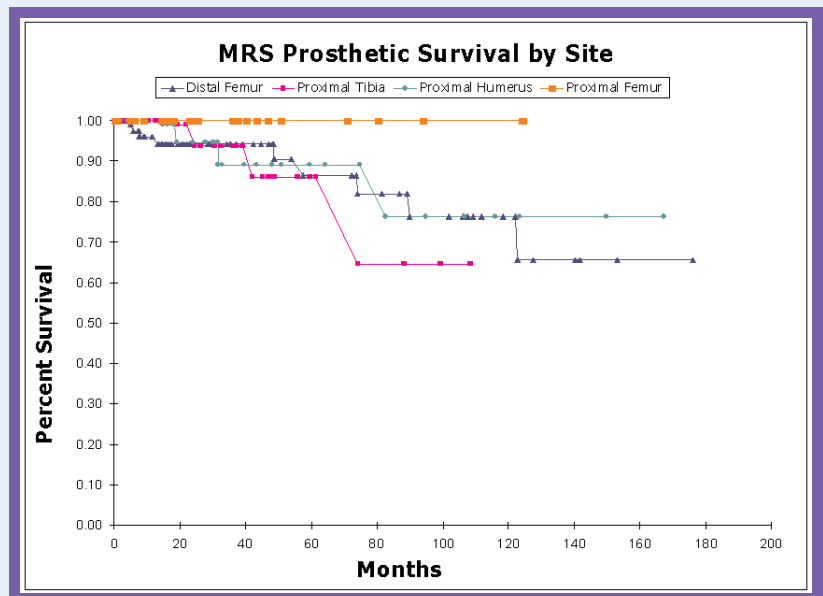
COMPLICATIONS BY PROSTHESIS TYPE	
prosthesis type, # complications	# failures
MSRS: 55 (32% of MSRS)	15 (8.8%)
custom segmental: 50 (62% of custom segmental)	22 (44%)
expandable: 5 (71% of expandable, includes lengthening)	2 (29%)
other: 0	0
BY COMPLICATION TYPE	
complication	# failures
prosthesis: 30 (33%)	19
soft tissue, superficial: 17 (19%)	0
soft tissue, deep: 10 (11%)	1
infection: 24 (26%)	17
dislocation: 5 (5.5%)	1
other: 5 (5.5%)	0

### COMPLICATIONS BY OUTCOME

Prosthesis retained: 52 (57% of complications)	-mean total surgeries: 3.0 -mean interval between 1st and 2nd surgeries: 17.6	
Prosthesis failed: 39 (42% of complications)	MSRS: 15 (8.7% of MSRS, 38% of failures)	9 infections -> 5 amputations
		5 prosthetic complications
		1 dislocation -> 1 amputation
	Custom Segmental: 22 (44% of custom, 62% of failures)	12 prosthetic complications
		8 infections -> 7 amputations
		1 soft tissue, deep complication -> 1 amputation
		1 other type complication
Expandable: 2		1 soft tissue, superficial
		1 prosthetic complication

### CONCLUSIONS

- Two out of three patients have only a single reconstructive surgery.
- For the 38% who had more than one surgical procedure, more than half (57%) were able to retain their prostheses.
- For modular prostheses, the complication rate was 32% with only 8.8% of prostheses failing.
- Aggressive management of soft tissue complications led to retention of the prosthesis in almost all cases.



14 patients underwent amputation solely due to surgical complications, while 7 patients underwent amputation for local recurrence, resulting in an impressive 91% limb salvage rate. This is in marked contrast to series where allograft reconstruction was used exclusively<sup>4-6</sup>.

The most difficult problem to manage remains deep infection.

### REFERENCES

- Bickels, J., et al., Reconstruction of the extensor mechanism after proximal tibia endoprosthetic replacement. *J Arthroplasty*, 2001. 16(7): p. 856-62.
- Malawer, M., Surgical technique and results of limb sparing surgery for high grade bone sarcomas of the knee and shoulder. *Orthopedics*, 1985. 8(5): p. 597-607.
- Wittig, J.C., et al., Osteosarcoma of the proximal humerus: long-term results with limb-sparing surgery. *Clin Orthop*, 2002(397): p. 156-76.
- Mankin, H.J., et al., Long-term results of allograft replacement in the management of bone tumors. *Clin Orthop*, 1996(324): p. 86-97.
- Brigman, B.E., et al. Allograft Reconstructions in Young Patients with High-Grade Sarcomas about the Knee. in *American Academy of Orthopaedic Surgeons*. 2002. Dallas, TX.
- Hornicek, F.J., Jr., et al., Limb salvage with osteoarticular allografts after resection of proximal tibia bone tumors. *Clin Orthop*, 1998(352): p. 179-86.

