

16

Resections in the Popliteal Fossa and the Posterior Compartments of the Leg

Jacob Bickels and Martin Malawer

OVERVIEW

Soft-tissue tumors of the popliteal fossa and the posterior compartments of the leg are relatively uncommon. Patients with such tumors formerly were treated with amputations; however, better understanding of tumor biology and advances in chemotherapy and radiation therapy now allow the performance of limb-sparing procedures in the majority of these cases. Most of these tumors are large and are in close proximity to the neurovascular bundle at presentation; therefore, careful preoperative evaluation and meticulous surgical technique are essential. The utilitarian approach enables wide and safe exposure of the popliteal fossa, superficial and deep posterior compartments of the leg, and the posterior aspect of the distal femur.

INTRODUCTION

Soft-tissue sarcomas and metastatic tumors of the popliteal fossa and posterior compartments of the leg have traditionally been treated with above-knee amputation. The major considerations governing the decision to amputate were the proximity to the neurovascular bundle and extent of soft-tissue involvement and resection. In addition, poor wound healing was expected as the result of the extensive resection, compromised blood supply to the surgical site, and the frequent need to administer adjuvant radiation therapy. Better understanding of the biological behavior of these tumors, the availability of effective chemotherapeutic agents, the administration of intra-arterial administration of chemotherapy, and techniques of isolated limb perfusion now allow the performance of limb-sparing procedures in the majority of these cases.

This chapter describes the utilitarian approach to the popliteal fossa and posterior compartments of the leg, a technique that allows wide exposure and safe resection of tumors in these anatomic sites. The approach can also be used for resection of intracapsular lesions of the knee joint or for intralesional resection of benign, benign-aggressive, and low-grade sarcomas of the posterior aspect of the distal femur (Figures 16.1–16.5).

ANATOMIC CONSIDERATIONS

The utilitarian approach to the popliteal fossa and posterior leg involves structures that, if damaged, can produce a permanent, significant disability. Therefore, thorough knowledge of the anatomy of the popliteal space and leg is mandatory. The popliteal space is diamond-shaped; on its superior aspect it is bounded by the semimembranosus and semitendinosus muscles medially and by the biceps femoris muscle laterally. Its inferior boundaries are the two heads of the gastrocnemius muscle. The roof of the fossa is the thin popliteal fascia; the floor is the posterior aspect of the distal end of the femur, the posterior capsule of the joint, and the popliteus muscle, which overlies the proximal tibia (Figure 16.6).

The tibial nerve enters the popliteal fossa lateral to the popliteal artery and approximately in the middle of the fossa, it crosses the artery to its medial aspect and remains at that location. The common peroneal nerve slopes down the superolateral border of the popliteal fossa toward the medial aspect and along the biceps femoris tendon, where it enters a tunnel within the substance of the peroneus longus muscle.

The popliteal artery enters the popliteal space from its medial aspect through the adductor hiatus and lies directly behind the posterior capsule of the knee joint. It runs obliquely through the fossa and branches into

two superior, single middle, and two inferior genicular arteries. The inferior genicular vessels pull the popliteal artery toward the joint capsule and usually have to be ligated in order to allow mobilization of the popliteal vessels to either side of the popliteal fossa. After exiting the popliteal fossa the popliteal artery divides into its terminal branches: the anterior tibial, posterior tibial, and peroneal arteries. The popliteal vein lies between the tibial nerve and the popliteal artery (Figures 16.7 and 16.8). The short saphenous vein pierces the popliteal fascia to join the popliteal vein within the fossa.

It is traditionally taught that the short saphenous vein and the medial sural cutaneous nerve are key anatomic structures in any popliteal dissection. Knowing the location of these two structures makes it easier to find the tibial nerve, which is the most superficial structure within the popliteal fossa (the popliteal vessels lie below the nerve). Tumors of the popliteal fossa and the proximal aspect of calf commonly displace the anatomic landmarks above and below the popliteal fascia, making the above-mentioned maneuver impractical. In order to locate the components of the neurovascular bundle, it is necessary to expose regions that are proximal and distal to the popliteal fossa, identify the major nerves and vessels, and follow them to the popliteal fossa. That surgical concept is used whenever a tumor creates distortion of the normal anatomic planes. Specifically, the sciatic nerve is tracked between the medial and lateral hamstrings, and the popliteal vessels are tracked between the two heads of the gastrocnemius muscle. Occasionally, it is necessary to detach the origin of the medial gastrocnemius muscle in order to achieve a wider exposure.

The muscles of the leg are enclosed within fascial layers that define four distinct compartments: anterior, lateral, superficial posterior (soleus and gastrocnemius muscles), and deep posterior (deep flexors, tibial nerve, posterior tibial and peroneal arteries and nerves). Tumors of the popliteal space and the superficial posterior compartment can usually be resected with marginal to wide margins. However, tumors of the deep posterior compartment are usually associated with extensive involvement of the neurovascular bundle and, therefore, necessitate amputation. Fortunately, most soft-tissue tumors of the posterior leg are located within the superficial posterior compartment and are confined either to the gastrocnemius or the soleus muscles, and therefore can be resected.

PREOPERATIVE EVALUATION

As in any tumor resection, complete preoperative staging is mandatory. Computed tomography (CT) and

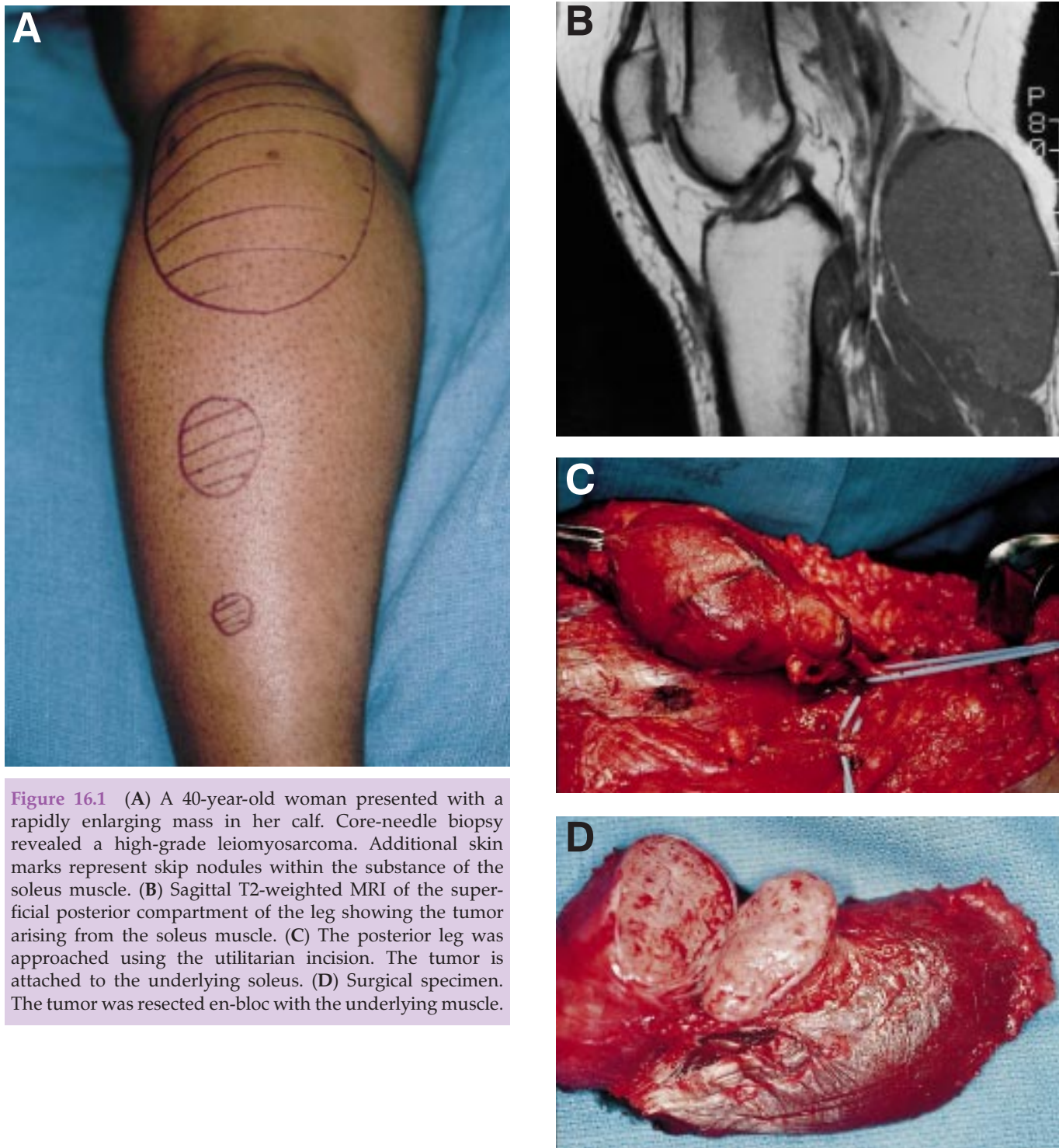


Figure 16.1 (A) A 40-year-old woman presented with a rapidly enlarging mass in her calf. Core-needle biopsy revealed a high-grade leiomyosarcoma. Additional skin marks represent skip nodules within the substance of the soleus muscle. (B) Sagittal T2-weighted MRI of the superficial posterior compartment of the leg showing the tumor arising from the soleus muscle. (C) The posterior leg was approached using the utilitarian incision. The tumor is attached to the underlying soleus. (D) Surgical specimen. The tumor was resected en-bloc with the underlying muscle.

magnetic resonance imaging (MRI) define the size of the tumor, the anatomic compartment to which it is confined, and its relation to the neurovascular bundle. The latter is best established with biplanar angiography, which also evaluates tumor vascularity and may assist

in the estimation of response to neoadjuvant chemotherapy, if given. Angiography is also essential in order to rule out vascular anomalies, which are relatively common in the tibioperoneal trunk. Bone scans are generally not helpful; however, increased uptake in an

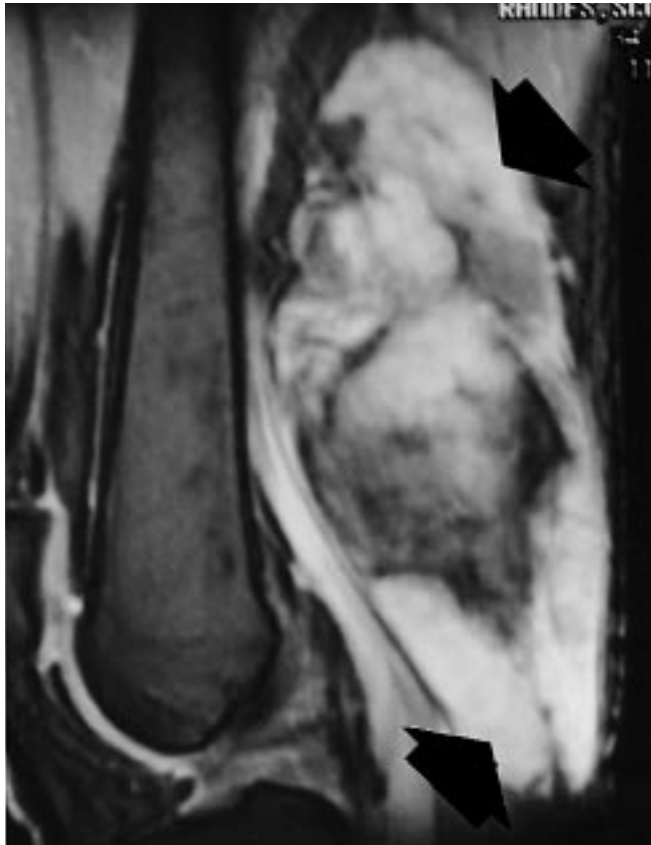

Figure 16.2 Intermediate-grade liposarcoma of the popliteal space. The lesion was approached through the popliteal component of the utilitarian incision, and marginal excision was performed. The patient was treated with adjuvant radiation therapy.

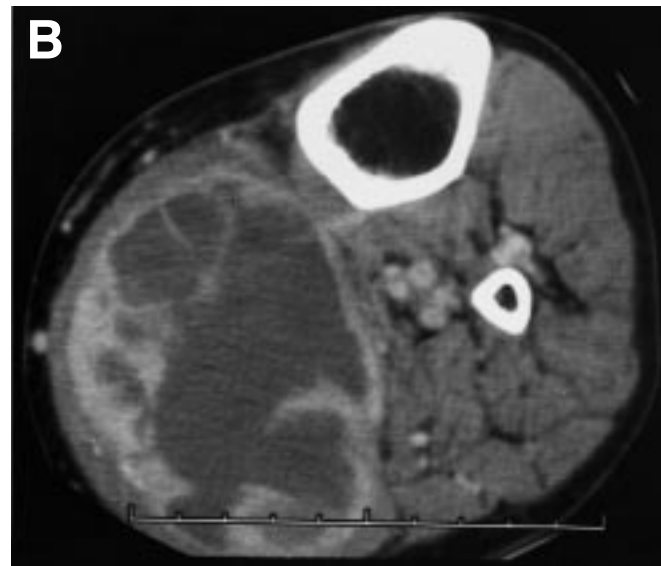
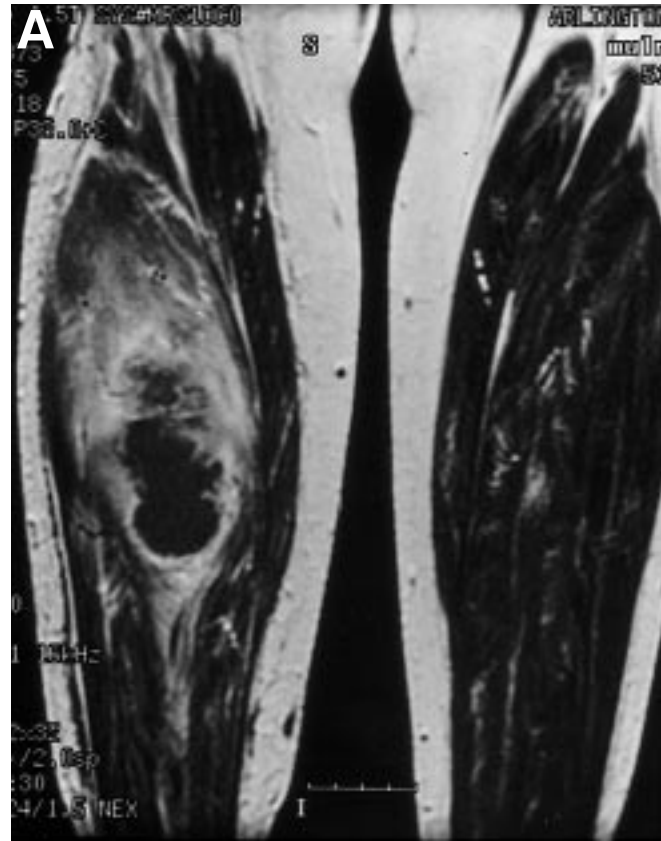


Figure 16.3 (A) Coronal T2-weighted MRI and (B) CT of the superficial posterior compartment of the leg showing a high-grade spindle-cell sarcoma within the soleus muscle.

adjacent bone suggests tumor extension and direct involvement.

SURGICAL TECHNIQUE

The patient lies prone on a frame with the operated extremity slightly flexed. The utilitarian approach to the popliteal fossa and posterior leg involves a curvilinear incision (Figure 16.9). The proximal limb of the incision follows the semitendinosus tendon distally to the level of the joint. It is curved laterally across the posterior aspect of the joint for about 5 cm and then turned distally along the lateral aspect or midportion of the posterior leg, depending on the aspect of the leg in which the lesion is located. The incision is extended to the level of the Achilles tendon (Figure 16.9). All or part of the incision can be used for adequate exploration and resection.

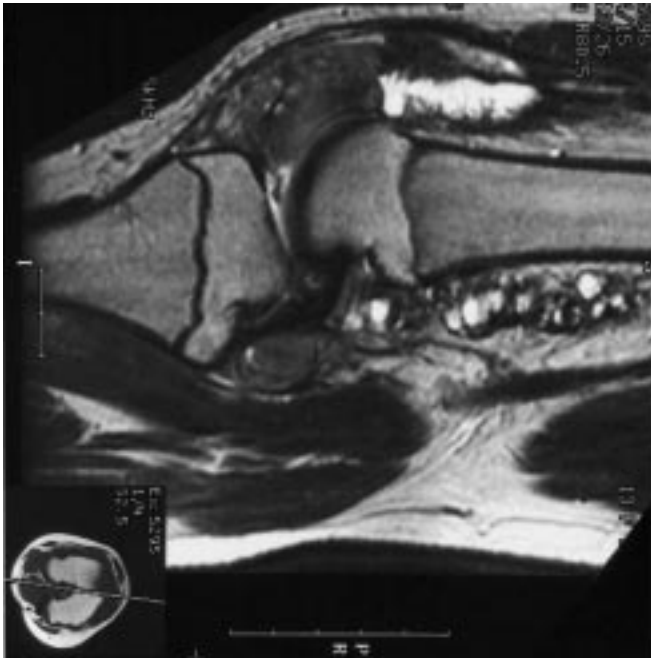


Figure 16.4 Pigmented villonodular synovitis of the knee joint in a 13-year-old patient. The patient underwent staged synovectomy (i.e. posterior synovectomy through the popliteal component of the utilitarian incision and anterior synovectomy a month later, once full range of motion was achieved) and adjuvant radiation therapy

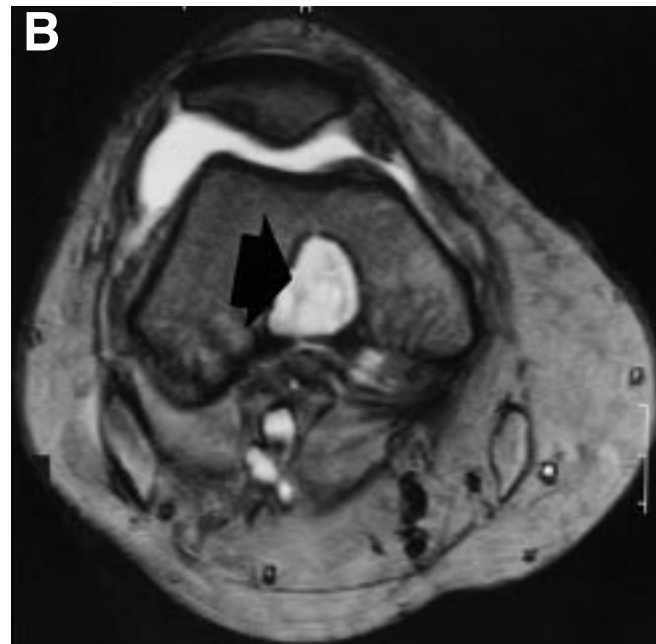
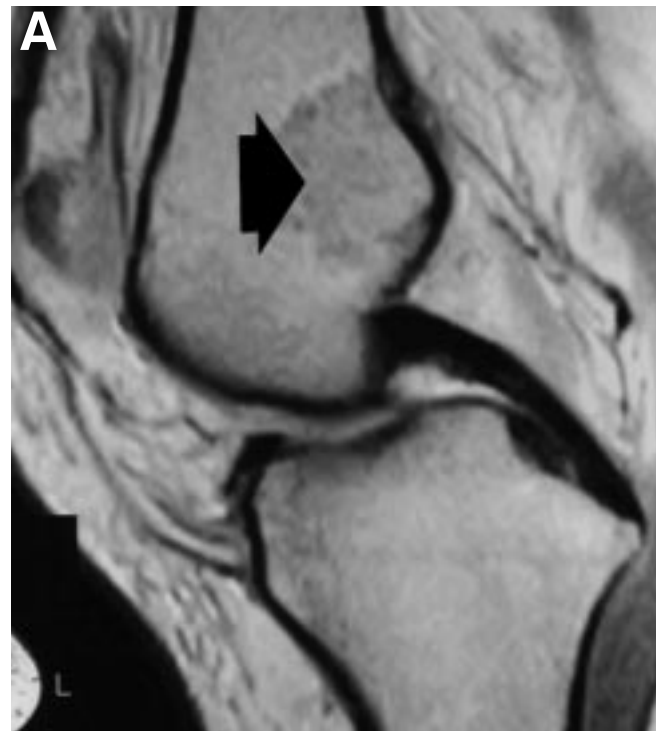

Figure 16.5 (A) Sagittal and (B) axial MRI of a low-grade chondrosarcoma of the posterior aspect of the distal femoral metaphysis. The tumor was approached through the popliteal component of the utilitarian incision.

The initial step of any resection around the popliteal fossa and posterior leg is exposure of the popliteal fossa and identification of the neurovascular bundle. This allows the surgical team to mobilize the vulnerable structures prior to resection. Skin flaps and subcutaneous tissues are raised and reflected. The popliteal fascia, which is very thin and friable, serves as a landmark because of its close proximity to the neurovascular bundle. Identification of the popliteal fascia is crucial, because if the surgeon does not realize that the dissection is underneath the fascia and only few millimeters of fatty tissue separate the blade from the neurovascular bundle, he may continue the dissection, assuming that he is still within the thick layer of popliteal fat, and may injure a component of the neurovascular bundle.

If posterior synovectomy or excision of a bone tumor from the posterior distal femur is planned, the neurovascular bundle is mobilized to one side and the joint capsule is opened using a longitudinal arthrotomy. The medial or lateral heads of the gastrocnemius muscles may be detached to facilitate exposure of the joint or the distal femur.

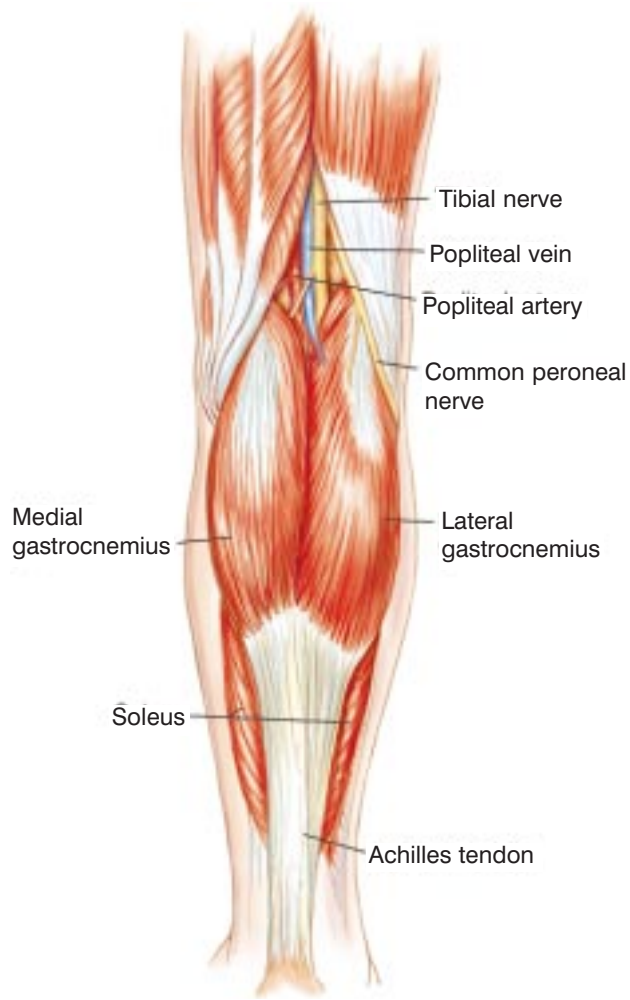


Figure 16.6 Anatomy of the popliteal fossa and the posterior compartments of the leg.

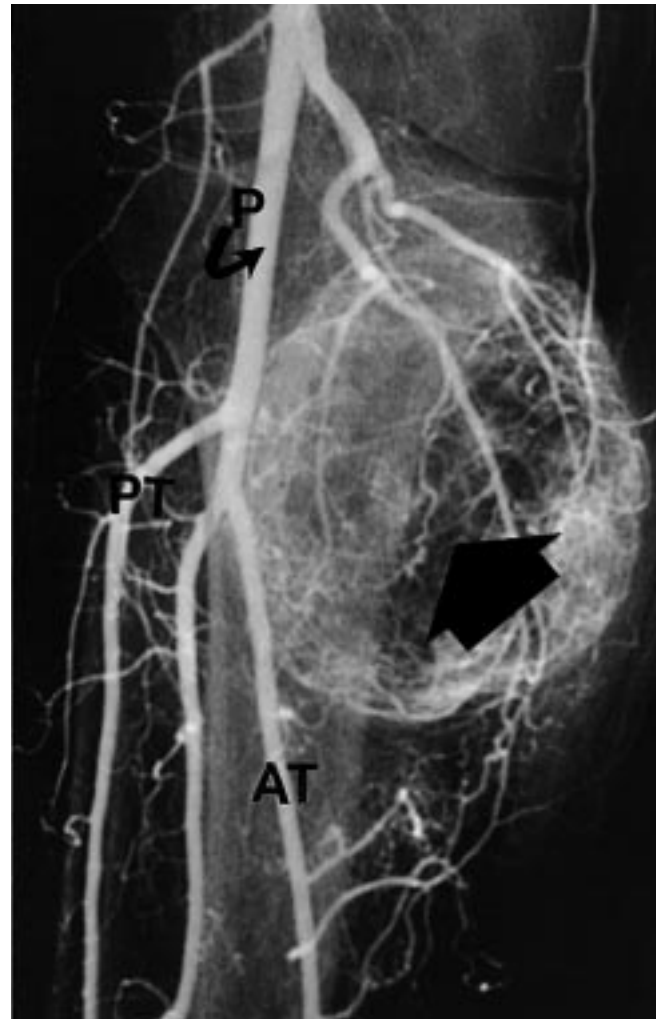


Figure 16.8 High-grade soft-tissue sarcoma of the medial gastrocnemius muscle. Popliteal angiogram shows a highly vascular lesion that receives its main blood supply from the medial sural artery. Further down, the popliteal artery divides into its terminal branches (the anterior tibial, posterior tibial, and peroneal arteries). Following neoadjuvant chemotherapy, en-bloc resection of the medial gastrocnemius and part of the soleus muscle was performed.

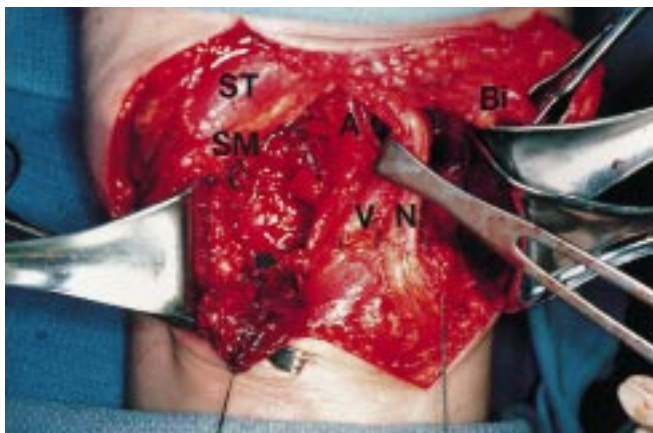


Figure 16.7 Wide exposure of the popliteal fossa. ST = semitendinosus muscle, SM = semimembranosus muscle, A = popliteal artery, V = popliteal vein, N = tibial nerve, Bi = biceps femoris tendon. Arrow points to the ligated inferior medial genicular artery.

If resection around the posterior compartments of the leg is planned, the skin incision is extended distally along the planned resection site. A lateral incision is used if resection of the lateral gastrocnemius is planned. A midline posterior incision is used for resections of the medial gastrocnemius, soleus, and deep posterior compartment (Figure 16.9). Unlike the dissection in the popliteal space, the fascia is dissected with the subcutaneous tissues and large fasciocutaneous flaps are raised. Using electrocautery, the two heads of the

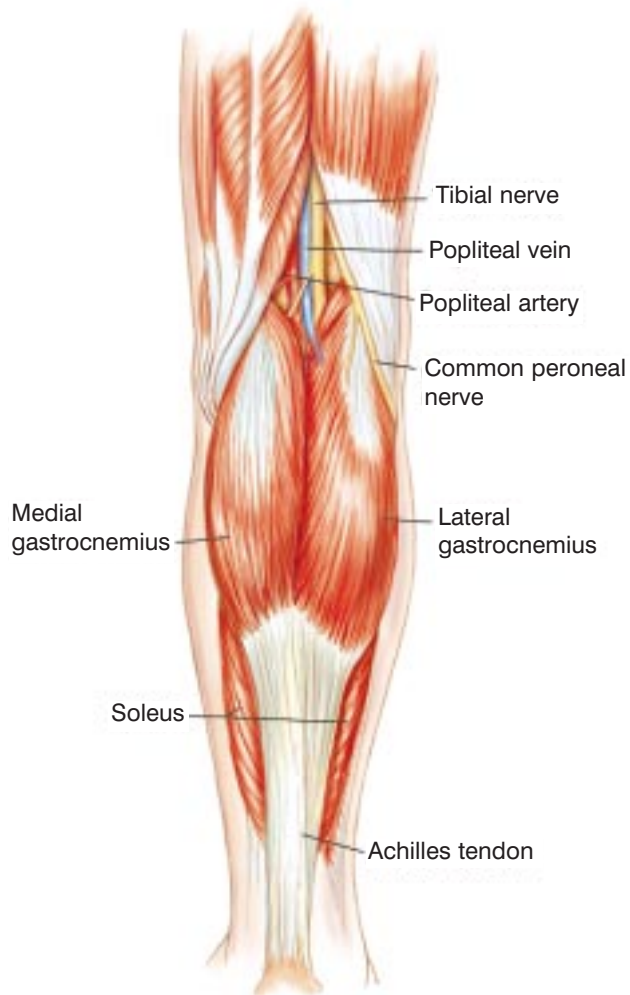


Figure 16.9 Utilitarian approach to the popliteal fossa and the posterior compartments of the leg. All or part of the incision can be used for adequate exploration and resection. Illustration shows tumors in the popliteal fossa, lateral gastrocnemius, and medial gastrocnemius muscles. A tumor in the popliteal fossa is approached through the popliteal component of the utilitarian incision (1-1). A tumor in the lateral gastrocnemius is approached through a lateral incision, and a tumor in the medial gastrocnemius or the soleus is approached through a midline incision (1-3-3).

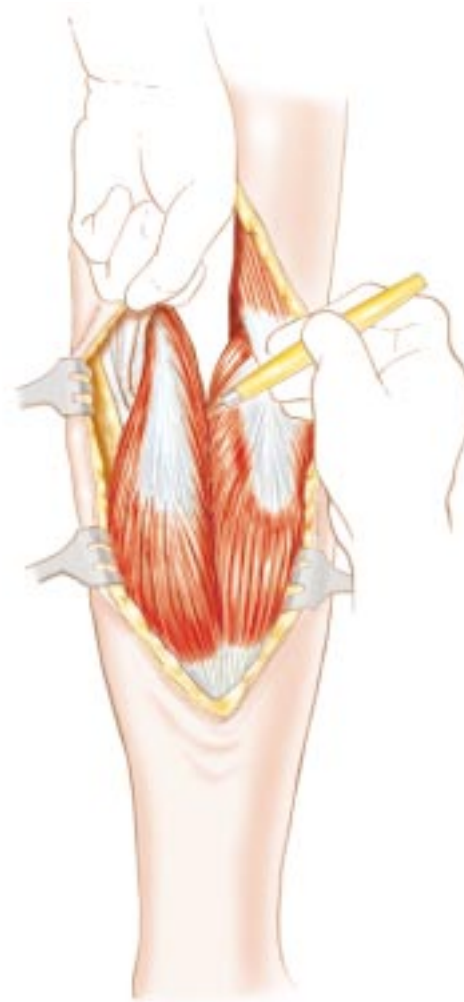

Figure 16.10 The interval between the medial and lateral gastrocnemius muscles is opened. The surgeon positions his finger between the gastrocnemius and soleus muscles to protect the neurovascular bundle that lies anterior to the soleus muscle, within the deep posterior compartment.

gastrocnemius flap are separated distally to the level of the Achilles tendon. The surgeon positions his finger between the gastrocnemius and the soleus muscles to protect the neurovascular bundle that lies anterior to the soleus muscle, within the deep posterior compartment (Figure 16.10). Radical excision of the medial or lateral heads of the gastrocnemius is achieved by reflection of the muscle, ligation of its main pedicle

(medial or lateral sural artery and vein, respectively), and transection of the femoral origin and insertion to the Achilles tendon.

Adequate exposure is essential for resection of the soleus. Proximally, it is achieved by reflection of the medial and lateral heads of the gastrocnemius. Partial or complete transection of the gastrocnemius femoral origin allows wide exposure of the proximal aspect of

the soleus, but imposes significant tension on the medial and lateral sural arteries, the main pedicles to medial and lateral gastrocnemius; it should therefore be practiced with caution. Distally, exposure is achieved by partial or, in rare cases, complete Achilles tenotomy (Figure 16.11).

By means of blunt dissection the soleus is separated from the transverse intermuscular septum, which outlines the deep posterior compartment. The soleus can then be detached from its tibial and fibular origins and calcaneal insertion. Appropriate plantar foot flexion can be preserved with just the medial gastrocnemius, lateral gastrocnemius, or soleus muscle. Any two of these structures may therefore be sacrificed without a significant impact on the range of motion around the foot. However, knee flexion can be significantly impaired under such circumstances. This is because the gastrocnemius muscle crosses the knee joint and the soleus muscle does not. Therefore, complete resection of the gastrocnemius will result in significant reduction in knee flexion capability, whereas resection of the soleus muscle and one of the heads of the gastrocnemius muscle will not.

If the joint capsule was opened, it must be closed prior to wound closure to avoid a potential synovial fistula. If part of the capsule was resected, and primary closure cannot be performed, one of the gastrocnemius heads or the popliteus muscle can be mobilized to seal the opening. The wound is closed over closed-suction drains. If extensive resection in the posterior leg was performed, a chest drain is added. To reduce tension on the suture lines, and avoid significant edema, the lower extremity is kept elevated in 15–20° of flexion in a posterior splint or a knee immobilizer for 3 days. Perioperative intravenous antibiotics are administered until the drainage tubes are removed. Postoperative mobilization with a knee immobilizer or posterior splint and weight-bearing as tolerated are required for about 3–4 weeks, depending on the extent of the soft-tissue resection and of satisfactory reconstruction. Active and active-assisted range of motion of the knee joint can then be introduced.

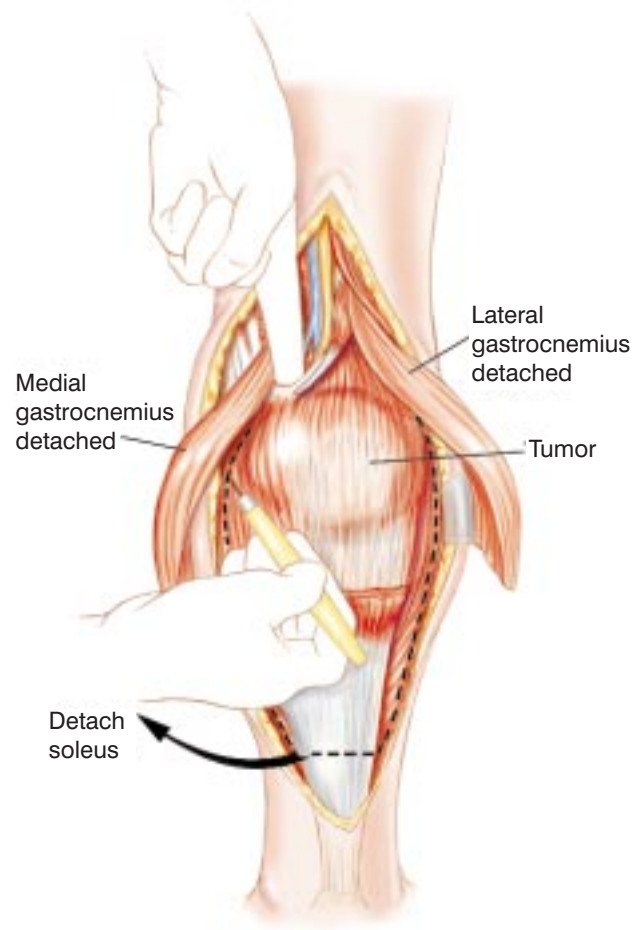


Figure 16.11 Exposure of the soleus muscle is achieved by reflection of the gastrocnemius heads and partial, or even complete, Achilles tenotomy, if necessary.