

## Constrained Total Scapula Reconstruction After Resection of a High-Grade Sarcoma

*James C. Wittig, MD\*;* *Jacob Bickels, MD\*\*;* *Felasfa Wodajo, MD\*\*;*  
*Kristen L. Kellar-Graney, BS\*\*;* *and Martin M. Malawer, MD\*\**

Patients with high-grade sarcomas arising from the scapula or periscapular soft tissues traditionally have been treated with either a total scapulectomy or a wide, en bloc, extraarticular scapular resection, termed the Tikhoff-Linberg resection. The major challenge after such resections is to restore shoulder girdle stability while preserving a functional hand and elbow. The current authors describe three patients who had an extraarticular, total scapula resection (modified Tikhoff-Linberg) for a high-grade sarcoma. Each patient had reconstruction with a constrained (rotator cuff-substituting) total scapula prosthesis in an effort to optimally restore the normal muscle force couples of both glenohumeral and scapulothoracic mechanisms. At latest followup, the Musculoskeletal Tumor Society functional score was 24 to 27 of 30 (80%–90%). All patients had a stable, painless shoulder and functional hand and elbow. Forward flexion and abduction ranged from 25° to 40°. Glenohumeral rotation (internal rotation, T6; external rotation –10°) below shoulder level, shoulder extension, and adduction were preserved. Protraction, retraction, elevation, and abduction of the scapula were restored and con-

tributed to shoulder motion and upper extremity stabilization. There were no complications. Total scapula reconstruction with a constrained total scapula prosthesis is a safe and reliable method for reconstructing the shoulder girdle after resection of select high-grade sarcomas. The authors emphasize the clinical indications, prosthetic design, surgical technique, and early functional results.

Patients with high-grade scapula and periscapular sarcomas often are treated with either an extraarticular scapula resection, termed a Tikhoff-Linberg resection or an intraarticular total scapulectomy.<sup>1–3,7,8,10–15</sup> The major goals after such resections are to restore shoulder girdle stability, preserve a functional hand and elbow, and prevent traction neurapraxia associated with a flail, hanging extremity. Early methods of reconstruction could be summarized as a nonanatomic approach to achieve stability of the upper extremity.<sup>2,3,5,7–9,12–15</sup> These methods ignored the functional importance of the periscapular muscles that often were spared from resection. Neither the glenohumeral nor scapulothoracic mechanisms were restored. The proximal humerus or remaining humeral shaft simply was stabilized with sutures or wires to the clavicle or a rib, either directly or indirectly through an interposed intramedullary rod or functional spacer. Active shoulder motion was absent. Instability was a problem and cosmesis

From the \*Department of Orthopedic Surgery, New York University Medical Center and the Hospital for Joint Diseases, New York, NY; and the \*\*Department of Orthopedic Oncology, Washington Cancer Institute at the Washington Hospital Center, Washington, DC.

Reprint Requests to Martin M. Malawer, MD, Department of Orthopedic Oncology, Suite C-2173, 110 Irving Street N.W., Washington, DC 20010.

was poor. Complications and failures occurred frequently.

To improve shoulder girdle stability and motion and upper extremity function, the senior author uses an anatomic approach to reconstruction, an approach that replaces the resected bony structures with a metallic total scapular prosthesis and that restores the normal muscle force couples of scapulothoracic and glenohumeral mechanisms.<sup>10</sup> This approach was made possible as a result of increasing experience with induction chemotherapy and limb salvage surgery, advances in prosthetic design, and the realization that the deltoid, latissimus dorsi, trapezius, levator scapulae, rhomboids, serratus anterior, and axillary nerve usually can be spared from resection and used to stabilize and power a prosthesis.

Traditionally, the senior author reconstructed the shoulder girdle with separate, nonconstrained scapula and proximal humerus prostheses. A Goretex aortic graft (WL Gore and Associates, Flagstaff, AZ) was used to reconstruct the capsule to prevent glenohumeral dissociation. The remaining periscapular muscles were tenodesed to predrilled holes in the scapular prosthesis allowing them to participate in scapulothoracic motion and stabilization of the entire construct. The deltoid and trapezius also were tenodesed to each other, providing active motion at the glenohumeral joint. Therefore, all remaining muscle force couples were restored. Although meticulous capsular reconstruction was done, the Goretex graft did not seem to be an optimal substitute for the rotator cuff and glenohumeral capsule because of the elasticity inherent to the material. Also, failure of the Goretex graft occasionally occurred, resulting in instability.

Recently, a constrained scapular prosthesis was developed to improve glenohumeral stability by passively restoring rotator cuff and glenohumeral capsular function. It consists of a constrained glenoid into which a proximal humeral prosthesis can be locked without compromising rotation (analogous to a bipolar hemiarthroplasty). The locking mechanism theoretically substitutes for the resected rota-

tor cuff during active glenohumeral motion by preventing upward humeral migration with deltoid contraction. Three patients who had an anatomic shoulder girdle reconstruction using a constrained total scapular prosthesis after an extraarticular total scapular resection for a high-grade sarcoma are described. Emphasis is given to the clinical indications, prosthetic design, surgical technique, and early functional results.

## MATERIALS AND METHODS

Three patients (all males) were treated with a modified Tikhoff-Linberg resection (extraarticular total scapula resection) for a high-grade sarcoma arising from the scapula or rotator cuff muscles. All three patients had reconstruction with a constrained total scapular prosthesis and modular proximal humeral prosthesis. The ages of the patients were 13 years, 17 years, and 26 years. Diagnoses included recurrent high-grade osteosarcoma along the inferior scapular neck, Ewing's sarcoma of the scapula, and large undifferentiated sarcoma arising from the subscapularis muscle. All patients were treated with chemotherapy before resection (neoadjuvant and induction chemotherapy). The followup ranged from 7 months to 2 years (one patient died 7 months postoperatively). Functional outcome was assessed at latest followup according to the Musculoskeletal Tumor Society Upper Extremity Functional Evaluation System<sup>6</sup> (Table 1).

## Clinical Indications

The procedure described here is suitable for selected patients with low- or high-grade sarcomas of the scapula or rotator cuff muscles and for large metastatic lesions that cause significant bone destruction.

The deltoid, trapezius, rhomboids, serratus anterior, and latissimus dorsi muscles, and the axillary nerve must be preserved at surgery. These muscles provide the important force couples needed to stabilize and motor the prosthesis. They all are required for sufficient soft tissue coverage and prosthetic suspension. The serratus anterior also protects the chest wall from scapular abrasion. Contraindications to this procedure include gross neurovascular (brachial plexus and axillary vessels) invasion, extension of tumor to involve the chest wall, and inability to spare the required mus-

**TABLE 1. Preliminary Results of the Three Patients**

Age	Gender	Diagnosis	Adjuvant Treatment	Followup (months)	Complications	Function
17	M	Ewing's sarcoma	Chemotherapy: Induction, Adjuvant	18	None	Shoulder: abduction and forward flexion, 30°–40°; internal rotation, T6 Hand and elbow: normal Scapula: + protraction and retraction, elevation
26	M	Undifferentiated-sarcoma arising from subscapularis	Chemotherapy: Induction, Adjuvant	7	None	Shoulder: abduction and forward flexion, 35°–45°; internal rotation, T6 Hand and elbow: normal Scapula: +protraction and retraction, elevation
13	M	Recurrent osteosarcoma	Chemotherapy: Induction, Adjuvant	24	None	Shoulder: abduction and forward flexion, 25°; internal rotation, T6 Hand and elbow: normal Scapula: + pro/retraction, elevation

+ = intact

cles and axillary nerve. The authors recommend that the final decision regarding the ability to use a prosthesis for reconstruction be made intraoperatively after exploring the tumor and determining its true local extent; it often is difficult to precisely determine tumor involvement of the required muscles based only on preoperative imaging studies.

### Prosthetic Design

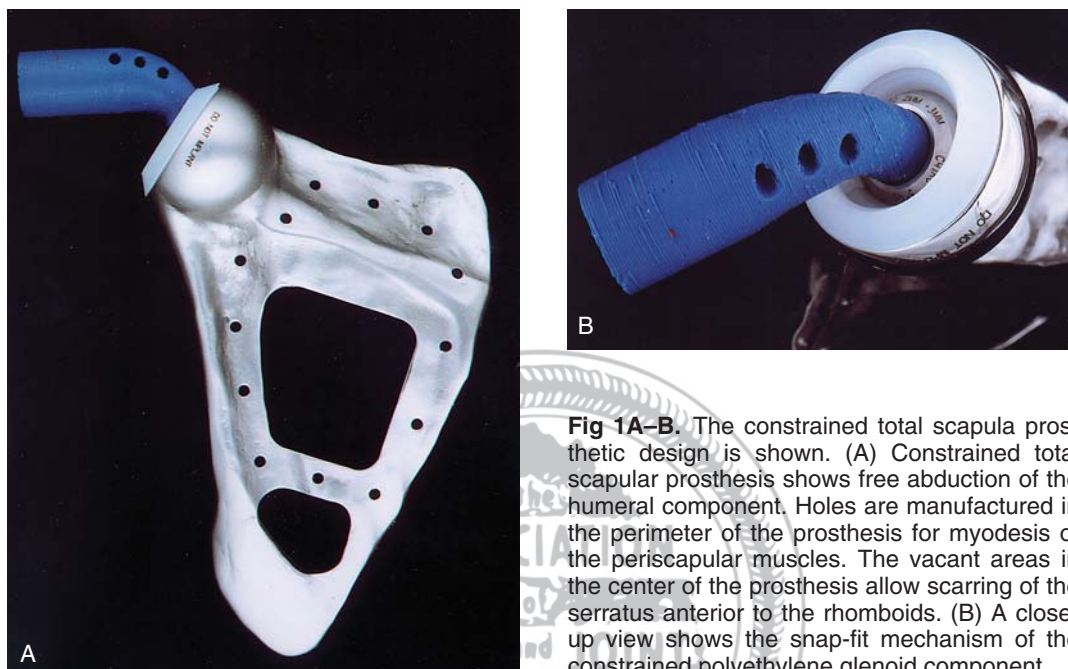
The body of the constrained scapular prosthesis (Howmedica-Osteonics, Allendale, NJ) is constructed from CoCr in the shape of a normal scapula (Fig 1). The lateral border, which may lie close to the neurovascular bundle, is curved and rounded. The glenoid is modeled after a bipolar proximal femoral replacement. It consists of a captured polyethylene liner into which the prosthetic humeral head (22 mm) can be snapped into place manually with a locking mechanism. The devices are manufactured in two sizes, adult and pediatric. Both sizes are smaller in comparison with normal scapulas in adults or children to facilitate muscle coverage. The scapular body has a large vacant area in the center for free communication between the anterior and posterior aspects of the prosthesis. Therefore, the muscles attached to the anterior and posterior aspects of the prosthesis can scar to each other, which helps suspend the prosthesis. There

are several holes along the axillary and vertebral borders of the prosthesis for suturing muscles directly to it.

### Surgical Technique

#### Resection

Anterior exploration and mobilization of the axillary sheath are required for most patients with scapular tumors because they frequently present with a large anterior component. Therefore, in most instances, an anterior approach is used and exploration of the brachial plexus is done initially. Resectability is determined. Once the tumor has been deemed resectable, the axillary, musculocutaneous, and radial nerves are identified and preserved. The anterior and posterior humeral circumflex vessels are identified and ligated. Patients with large anterior masses also require ligation of the upper and lower subscapular nerves, thoracodorsal nerve, and subscapular artery. This step enables mobilization of the plexus and vessels from the scapula, proximal humerus, and tumor. A posterior approach then is done. The incision extends along the lateral border of the scapula and curves medially at its tip. A large, posterior, medially-based fasciocutaneous flap is developed. The tumor is explored and its extent is determined. The requisite muscles must not be involved by tumor. All



**Fig 1A–B.** The constrained total scapula prosthetic design is shown. (A) Constrained total scapular prosthesis shows free abduction of the humeral component. Holes are manufactured in the perimeter of the prosthesis for myodesis of the periscapular muscles. The vacant areas in the center of the prosthesis allow scarring of the serratus anterior to the rhomboids. (B) A close-up view shows the snap-fit mechanism of the constrained polyethylene glenoid component.

periscapular muscles are sequentially identified and released. The deltoid, trapezius, rhomboids, levator scapulae, latissimus dorsi, and serratus anterior are preserved for later reconstruction. Clavicular and humeral osteotomies are done. The tumor is removed en bloc with the scapula, rotator cuff, proximal humerus, and distal  $\frac{1}{2}$  of clavicle.

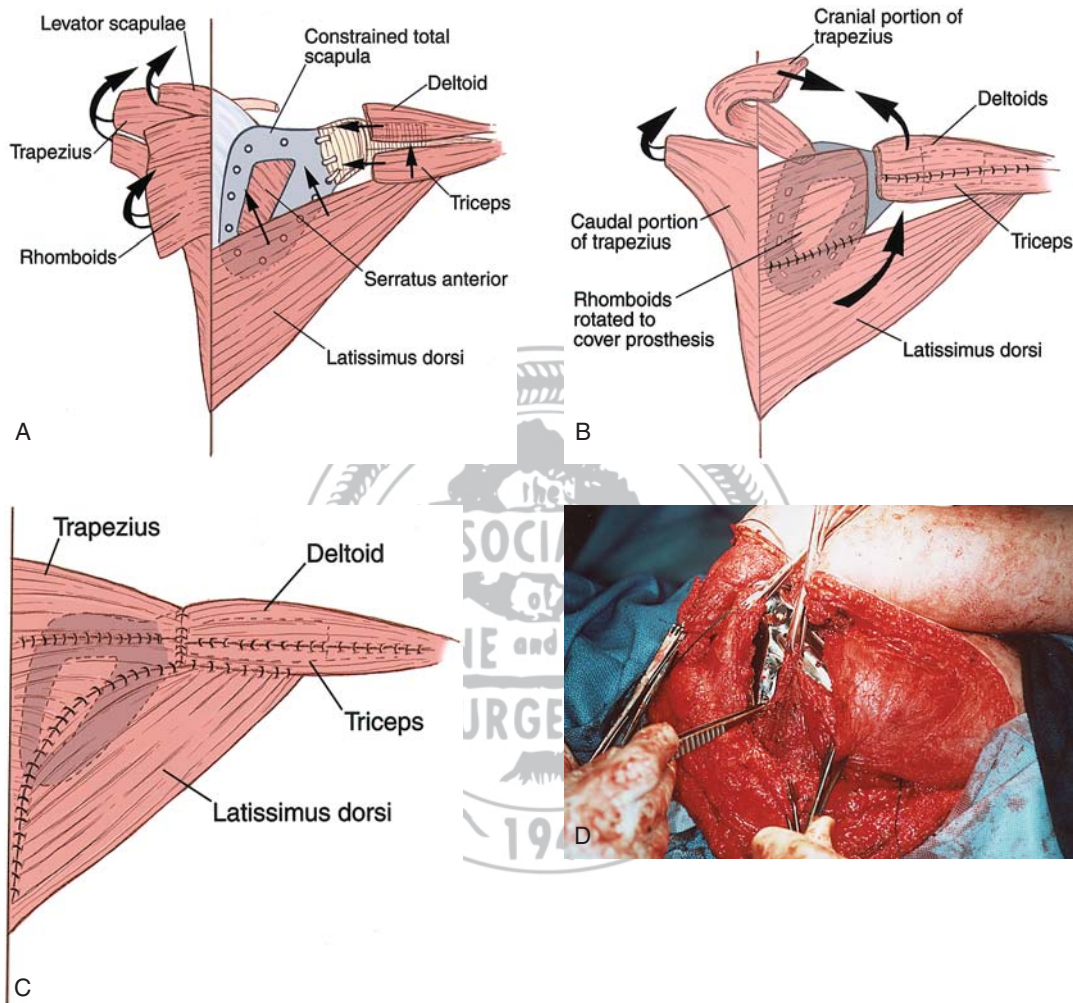
#### Scapular Reconstruction

The scapular prosthesis is placed in a pocket between the serratus anterior and the rhomboids. Superiorly, the trapezius muscle is tenodesed to the deltoid muscle. The distal  $\frac{2}{3}$  of the prosthesis is covered by the latissimus muscle (Fig 2). The latissimus is mobilized and rotated superiorly to ensure sufficient coverage of the prosthesis. It is extremely important to position the prosthesis close to the spine, within 1 to 2 cm of the midline, at the same level as the contralateral scapula. This facilitates complete soft tissue coverage and prevents anterior gliding of the prosthesis, thus protecting the neurovascular bundle and improving cosmesis. The surrounding musculature is reattached to the holes in the prosthesis with 3-mm nonabsorbable tapes. The rhomboids are sutured to holes along the vertebral border; the trapezius and deltoid are sutured to the superior border; and the latissimus dorsi is sutured

to the axillary border of the prosthesis. The periscapular muscles then are tenodesed to each other with Number 0 braided, nonabsorbable suture. A modular proximal humerus is cemented into the remaining distal humerus; its length can be adjusted easily. The humeral length usually is chosen to allow shortening of the extremity by 1 to 2 cm, which relieves tension on nerves and vessels and eases deltoid and trapezius attachment and wound closure. In the three cases reported here, it was decided to continue using a Goretex aortic graft because it facilitates muscular attachment to the proximal humerus and for extra protection against glenohumeral dissociation should the constrained glenoid fail. The aortic graft is sutured to holes around the glenoid neck and passed over the head of the humerus and sutured through holes in the humeral neck. Muscles are reattached to cover the entire proximal humerus (pectoralis to the prosthesis and to the deltoid and trapezius). Tenodesis of the biceps tendon to the pectoralis major is done with the elbow in 45° flexion and the hand fully supinated.

#### Patient 1

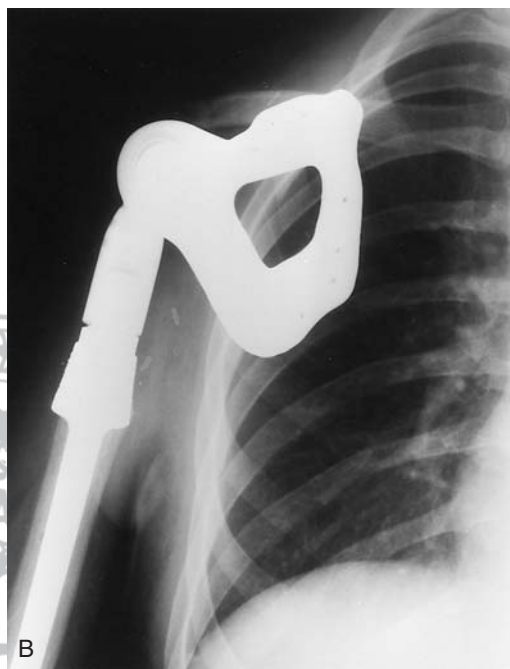
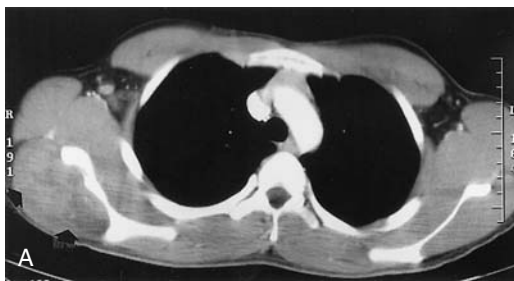This case exemplifies constrained total scapular reconstruction after Tikhoff-Linberg resection of the scapula for Ewing's sarcoma. The patient was a 17-



**Fig 2A–D.** Scapular reconstruction is shown. (A) The scapular prosthesis is positioned in a pocket between the serratus anterior and the rhomboids. It is crucial that the scapular prosthesis be positioned as close to midline as possible (1 to 2 cm from the spine). (B) The rhomboids and the serratus anterior are tenodesed to the posterior and anterior aspects of the prosthesis, respectively. The trapezius, deltoid, and levator scapulae are tenodesed to the prosthesis and to each other. The latissimus dorsi is mobilized to close any remaining soft tissue defect. (C) The entire prosthesis is covered with muscle. (D) This intraoperative photograph shows mobilization of the latissimus dorsi and rhomboids for soft tissue coverage and suspension of the prosthesis. 2A-C reprinted with permission from Malawer M, Wittig J, Rubert C: Scapulectomy. In Malawer MM, Sugarbaker P (eds.). *Musculoskeletal Cancer Surgery: Treatment of Sarcomas and Allied Diseases*. Norwell, MA, Kluwer Academic Publishers, 2001. p. 553–568.

year-old boy who presented with pain and swelling of the right shoulder. Physical examination showed a large mass surrounding the scapula. The right upper extremity was neurovascularly intact. Plain radiographs revealed a permeative lesion of the right scapula. Magnetic resonance imaging (MRI) scans

and computed tomography (CT) scans confirmed a large mass protruding anteriorly and posteriorly from the scapula. Biopsy revealed a Ewing's sarcoma. Induction chemotherapy was administered and caused a dramatic reduction in the size of the extrasosseous component (Fig 3). Repeat CT scans



**Fig 3A–B.** One patient had a large Ewing's sarcoma from the right scapula and was treated with induction chemotherapy followed by limb-sparing surgical resection (A) A CT scan taken at presentation shows a large Ewing's sarcoma arising from the right scapula. Arrows delineate the extensive soft tissue component of the tumor. A repeat CT scan of the same lesion taken after induction chemotherapy showed complete regression of the soft tissue component of the tumor improving the ability to preserve the muscles necessary for prosthetic reconstruction. (B) An anteroposterior radiograph of the same patient was obtained after reconstruction with the constrained total scapula and modular proximal humerus prostheses.

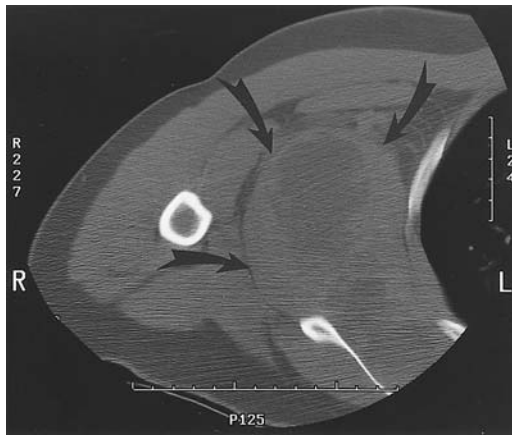showed complete regression of the extraosseous component. It now was possible to salvage several muscles needed for prosthetic reconstruction. The patient had a modified Tikhoff-Linberg resection and reconstruction with the constrained total scapular prosthesis. There were no intraoperative or postoperative complications.

At 1.5 years postoperatively, the patient has a stable, painless shoulder. Active shoulder abduction and flexion is 30° to 40°, internal rotation is normal, and external rotation is to neutral. Passive motion is normal. Shoulder abduction strength is Grade 3. Shoulder elevation strength (shrugs) is Grade 5. Protraction and retraction of the scapula remain intact. The periscapular muscles contract when the patient carries objects. Elbow range of motion (ROM) is normal, and biceps and triceps strength are Grade 5. Hand sensation and motor function are normal. The patient can do push-ups. The patient had pulmonary metastases develop 14 months after surgery and currently is alive with evidence of disease and is receiving additional chemotherapy.

#### *Patient 2*

This case shows a modified Tikhoff-Linberg resection in lieu of a forequarter amputation for a large,

primary, undifferentiated sarcoma arising from the subscapularis muscle and invading the scapula. A constrained total scapula and a modular proximal humerus prosthesis were used for reconstruction. This patient, a 26-year-old man, presented with a 9 × 7 × 11-cm mass arising from the anterior surface of the right scapula (Fig 4). Computed tomography scans of his chest revealed multiple bilateral pulmonary nodules. He had restricted ROM of the shoulder and paresthesias in his right hand. Biopsy showed a high-grade undifferentiated sarcoma. On the basis of these clinical findings, a forequarter amputation ordinarily would have been recommended; however, induction chemotherapy was used to kill the tumor with the hope that a limb-sparing procedure could be done. An institutional high-risk chemotherapy protocol that includes vincristine, cyclophosphamide, doxorubicin, etoposide, and ifosfamide was initiated. After three cycles of chemotherapy, the patient reported softening of the mass and diminished paresthesias in his hand. Staging studies were repeated. Angiography and venography confirmed patency of the axillary vessels. After the fourth cycle of chemotherapy and 5 months after initial presentation, the patient had an extraarticular total scapula resection. Initial exploration



**Fig 4.** A CT scan shows a large primary undifferentiated sarcoma arising from the right subscapularis muscle (arrows). This scan was taken after a protocol of induction chemotherapy.

showed that the brachial plexus was free of tumor. The deltoid, trapezius, remaining periscapular muscles, and the axillary nerve were preserved. Reconstruction was accomplished with a constrained total scapula and a proximal humeral prosthesis. Pathologically, all surgical margins were negative and there was 40% tumor necrosis. There were no intraoperative or postoperative complications.

Followup up 7 months postoperatively showed a stable, painless shoulder. There was no evidence of local recurrence. Active shoulder ROM was 45° abduction, 45° forward flexion, external rotation to neutral, and full internal rotation. Active scapular motion was restored. The elbow and hand retained normal function. The patient's pulmonary disease continued to progress and he died 7 months postoperatively.

### Patient 3

This case shows revision of an intraarticular proximal humerus resection to an extraarticular, total scapular resection for recurrent osteosarcoma. The patient was a 13-year-old boy with telangiectatic osteosarcoma of the proximal humerus. Initially, he presented with a pathologic fracture through a 6- × 8-cm osteolytic lesion of the right proximal humerus. An intraarticular resection of the proximal humerus was done by surgeons in another institution (Fig 5). The defect was reconstructed by fixing a free, nonvascularized, autogenous fibula to the remaining humerus with an intramedullary metal-

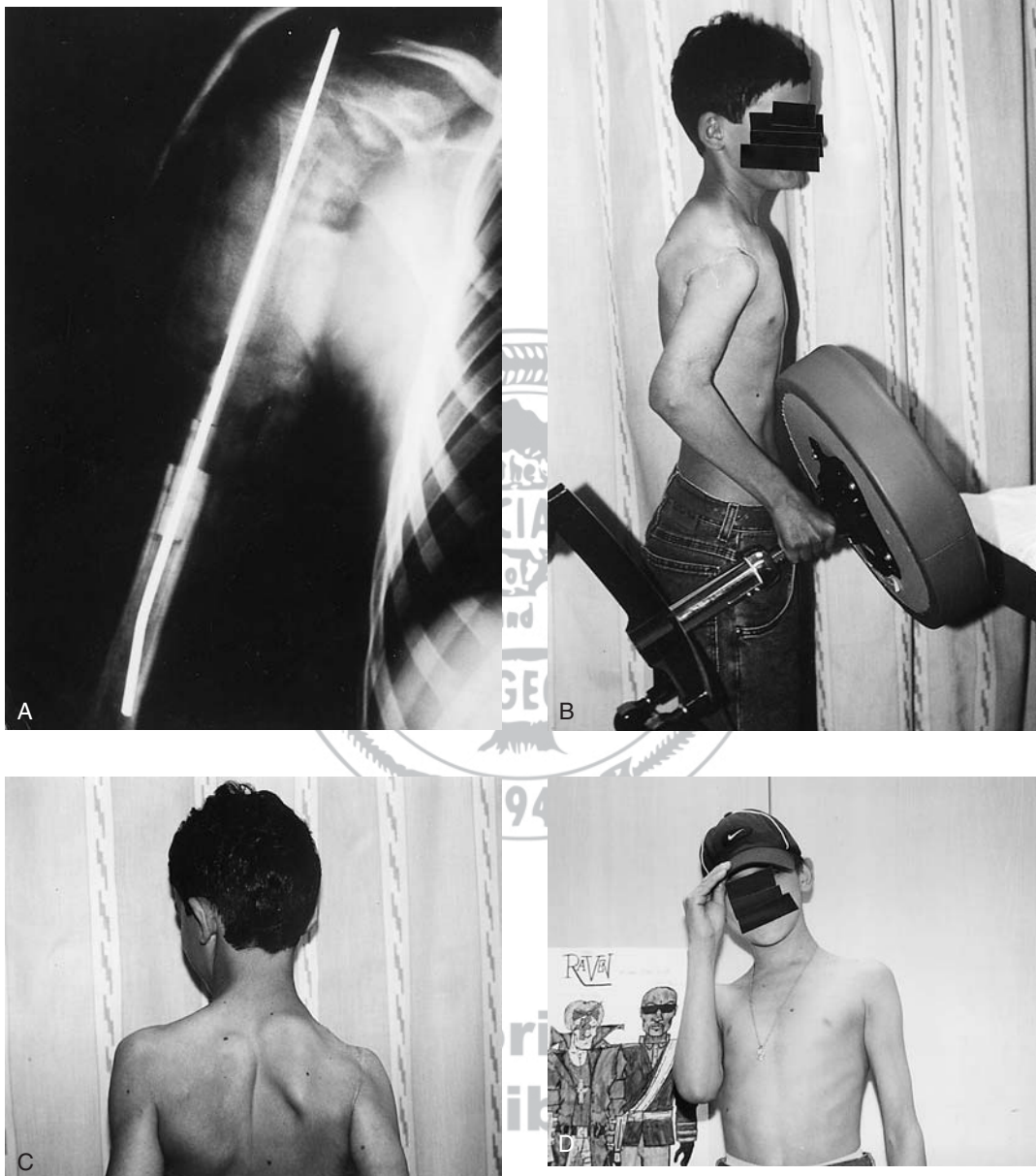lic pin. Two to 3 months postoperatively, the pin began protruding through the skin.

The family sought a second opinion. By that time, local recurrence had developed along the inferior glenoid and scapular neck. Restaging studies were done. The patient had three cycles of neoadjuvant chemotherapy consisting of doxorubicin and cisplatin. A scapulectomy was done and the old construct was removed en bloc, which converted the initial intraarticular resection to a modified, Tikhoff-Linberg resection. Reconstruction of the scapula and proximal humerus was accomplished with constrained total scapular and modular proximal humeral prostheses. There were no intraoperative complications. The patient's shoulder was placed in a sling for 2 weeks and then a gentle physical therapy program was started. All skin flaps healed.

At 2 years postoperatively (Fig 5), the patient has a stable, painless shoulder. His shoulder has 25° active abduction and flexion, internal rotation to T6, and external rotation to -10°. Passive shoulder motion is normal. Active elbow motion ranges from 0° to 130°. Shoulder abduction and forward flexion are Grade 3. Internal rotation, adduction, and extension strength are Grade 5. Elbow flexion and extension strength are Grade 5. The patient can actively protract, retract, elevate, and depress his scapula. When lifting heavy objects, his periscapular muscles actively contract to stabilize his scapula and upper extremity. Hand sensation and motor function are normal. The patient is free of local and systemic disease.

## RESULTS

Function for all three patients, as evaluated according to the Musculoskeletal Tumor Society Upper Extremity Functional Evaluation System,<sup>6</sup> was 24 to 27 of 30 (80%–90%). The following grades were assigned to each category assessed by the Musculoskeletal Tumor Society system: pain, 5; hand dexterity, 5; emotional acceptance, 5; lifting ability, 3 to 4; hand positioning, 3 to 4; function and activities, 3 to 4. In all three patients, a painless, stable shoulder girdle was restored. All patients retained a functional hand and elbow. No patient required a forequarter amputation. Rotation below the shoulder level, which is required for most activities of daily living and personal hygiene, was preserved (range, -10°



**Fig 5A–D.** Conversion of an intraarticular proximal humerus resection and reconstruction to a Type VI resection for recurrent osteosarcoma are shown. (A) A radiograph of a 13-year-old boy who presented 3 months after an intraarticular resection for a telangiectatic osteosarcoma of the proximal humerus is shown. At presentation, in addition to the rod protruding through the skin, a local recurrence was detected along the inferolateral border of the scapula. (B) A clinical photograph taken 6 months after the procedure shows that elbow flexion strength is almost normal. The periscapular muscles contract to help stabilize the upper extremity. (C) The periscapular muscles, trapezius, and rhomboids contract to stabilize the upper extremity when the patient carries a heavy load. (D) The patient can place his hand above shoulder level for activities of daily living. A video is available on CORRONLINE ([www.corronline.com](http://www.corronline.com)).

external rotation to T6 for internal rotation). Internal rotation, adduction, and extension strength were Grade 5. Active shoulder abduction and forward flexion (combined glenohumeral and scapulothoracic motion) ranged from 25° to 45° and were Grade 3 motor strength. Each patient was capable of scapular protraction, retraction, and elevation and the periscapular muscles contracted when carrying objects, thus assisting in upper extremity stabilization. Elbow flexion and extension strength were Grade 5. Hand sensation and dexterity were normal and grip strength was Grade 5 for each patient.

All three patients could reach the top of their head, opposite shoulder and armpit, and perineal area with their hand. There were no limitations in activities of daily living including feeding, dressing, and personal hygiene. Lifting ability was normal with the arm at the patient's side. Cosmesis was acceptable to all three patients. The only limitations were in recreational (high intensity athletics) and other activities that required raising the extremity above shoulder level. There were no intraoperative or postoperative complications. No patient had a traction neurapraxia develop. One patient died of disease 7 months postoperatively.

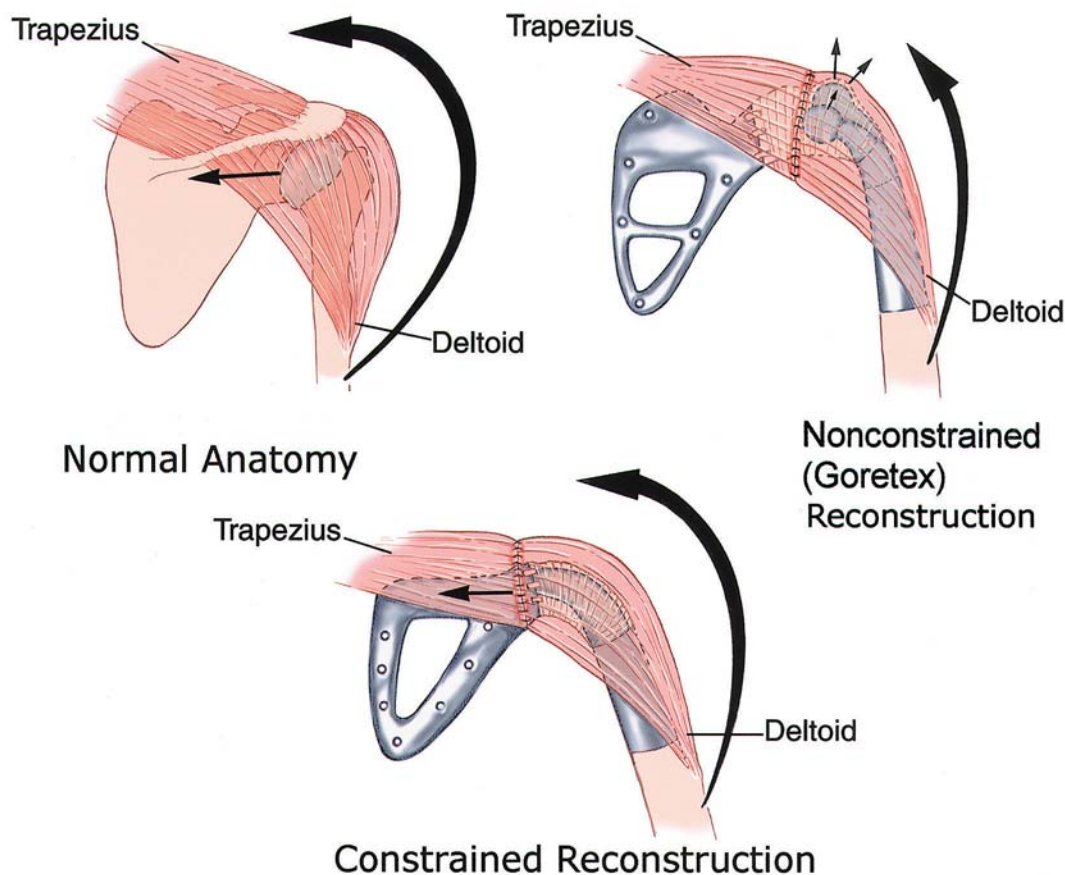
## DISCUSSION

This is the first report of a constrained total scapula prosthesis used for reconstructing the shoulder girdle after resection of a high-grade scapula or periscapular sarcoma. Based on preliminary results, this method of reconstruction seems to be a safe and reliable option for limb-sparing surgery after total scapulectomy or an extraarticular scapular resection for selected tumors. It provides an anatomic method of reconstruction that restores glenohumeral and scapulothoracic mechanisms by recreating the normal muscle force couples around the shoulder girdle. The constrained glenoid was designed to passively restore the dynamic stability normally provided by the rotator cuff, prevent glenohumeral dissociation and ease surgical reconstruction. Similar to the rotator cuff, it pro-

vides a strong restraint against superior humeral migration with deltoid contraction without restricting rotation. This may translate into better shoulder abduction, flexion, and stability compared with earlier, nonconstrained versions of total scapular prostheses that used Goretex aortic graft for reconstructing the glenohumeral joint capsule, which was more elastic in nature (Fig 6).

The preliminary functional results of the upper extremity and active shoulder ROM achieved in the three patients reported in the current study are at least equivalent to many of the long-term results obtained with earlier nonconstrained designs.<sup>1</sup> The Musculoskeletal Tumor Society functional rating for these patients was 24 to 27 of a maximal score of 30 points or 80% to 90%. All three patients received the best possible score (5 points) in the areas of pain, hand dexterity, and emotional acceptance. Patients lost points in the areas of function, hand positioning, and lifting ability. The scoring of these areas was subjective; therefore a range of 3 to 4 was assigned to each of these areas. All patients had some restrictions in activities, mostly high level athletics, although all were capable of some recreational activities. Hand positioning was not unlimited but all patients could place their hand above shoulder level, touch the back of their head, and feed themselves. Lifting ability was normal with the arm adjacent to the body; however, none of the patients could lift objects significantly above shoulder level. These results are comparable with the functional results reported by Asavamongkolkul et al<sup>1</sup> who reported an average Musculoskeletal Tumor Society score of 74% for 14 patients who had reconstruction with a nonconstrained (Goretex-stabilized) total scapula prosthesis after resection of a tumor between 1980 and 1997. The study by Asavamongkolkul et al<sup>1</sup> is the only other report in the literature describing total scapula prosthetic reconstruction after tumor resection.

Additional followup of the current patients is necessary to determine whether active shoulder motion, specifically abduction and for-



**Fig 6.** Muscle force vectors across the glenohumeral joint are shown. Under normal conditions, the rotator cuff provides a medially and inferiorly directed force vector on the humeral head that stabilizes it against the glenoid. Contraction of the deltoid is converted efficiently into angular acceleration of the glenohumeral joint (large arrow) that results in abduction. When a Goretex aortic graft is used to stabilize separate total scapular and proximal humerus components, the inherent elasticity in the Goretex permits upward humeral migration with deltoid contraction. Deltoid contraction is not converted efficiently into angular acceleration of the glenohumeral joint (small arrow). The constrained glenoid mechanically ensures stability and theoretically restores rotator cuff function. It stabilizes the humeral head within the glenoid and prevents upward humeral migration. Deltoid contraction can be converted efficiently into angular acceleration (abduction) of the glenohumeral joint. (Reprinted with permission from Malawer M, Wittig J, Rubert C: Scapulectomy. In Malawer MM, Sugarbaker P (eds). *Musculoskeletal Cancer Surgery: Treatment of Sarcomas and Allied Diseases*. Norwell, MA, Kluwer Academic Publishers 553–568, 2001.)

ward flexion, and strength will be improved and the risk of glenohumeral instability minimized with the new, constrained component. It is anticipated that active shoulder motion and strength will continue to improve with rehabilitation in the two living patients. Based on the experience of the senior author with

nonconstrained scapula replacements, function improves gradually during the first 2 years postoperatively.

Before 1970, most patients with high-grade sarcomas arising from the scapula were treated with a forequarter amputation. The first limb-sparing surgeries for high-grade sarcomas aris-

ing from the shoulder girdle were reported by Marcove et al<sup>12</sup> in 1977.<sup>12</sup> They reported the Tikhoff-Linberg resection achieved local tumor control and survival similar to that achieved with a forequarter amputation. Most importantly, a functional hand and elbow were preserved. Limb-sparing surgery for patients with high-grade sarcomas in this location soon become standard treatment.<sup>2-4,11,13,14-16</sup>

In the earliest experience with limb-sparing surgery for tumors of the scapula, there was no effort to reconstruct the shoulder girdle after resection.<sup>2,7,10,12-14</sup> Shoulders were left flail and the extremity was left dangling by the skin and neurovascular bundle. There was no active shoulder motion. This combined with shoulder instability led to difficulty with carrying objects and placing the hand into a functional position necessary for activities of daily living. Cosmesis was poor and traction neuropathia frequently developed, which led to chronic pain and motor and sensory deficits. Many patients required an external orthosis for support.

Surgeons attempted to circumvent many of these problems by either stabilizing the proximal humerus or remaining humeral shaft directly to the clavicle or a rib with heavy sutures or wires.<sup>2,4,8,9,12,13</sup> They also attempted placing an intramedullary rod or other type of functional spacer into the remaining humeral shaft and stabilizing its proximal end. Shoulder motion was not improved and shoulder instability still was a problem. Complications and failures were frequent and included sutures and wires rupturing, and rods eroding through the overlying skin and abrading the chest wall. Patients eventually ended up with a flail, painful shoulder or an amputation.

These early methods of reconstruction are referred to as nonanatomic methods because they made no attempt to reconstruct the bony structures that were resected nor restore the normal muscle force couples responsible for scapulothoracic and glenohumeral motion. The periscapular muscles (rhomboids, deltoid, trapezius, serratus anterior) were deemed to be

of no functional value and either were resected routinely, or, if preserved, not used for reconstruction. O'Connor et al<sup>13</sup> reported on the functional results of eight patients who were treated with a total scapulectomy or Tikhoff-Linberg resection. The shoulders in three patients were left flail (no reconstruction). The average Musculoskeletal Tumor Society score was 44%. Five patients had reconstruction with a functional spacer. The average Musculoskeletal Tumor Society score for this group was 49%. These patients received unsatisfactory scores (< 3) in the areas of function, hand positioning, and lifting ability. These results are inferior to the results reported in the current study and those reported by Asavongkulkul et al,<sup>1</sup> as cited previously.

Damron et al<sup>5</sup> also reported on the functional outcome of 14 patients treated with a modified or classic Tikhoff-Linberg procedure who had reconstruction with a functional spacer. Active shoulder motion was reported as a percentage of the uninvolved side as follows: abduction, 5% to 15%; internal rotation, 5% to 10%; external rotation, 0% to 5%; shoulder flexion, 5% to 20%; and shoulder extension, 35% to 45%. These results also seem to compare inferiorly with the preliminary results reported in the current study. In the three patients reported in the current study, internal rotation is almost normal, shoulder abduction and flexion are approximately 20% to 25% of the uninvolved side, and extension is the same as the uninvolved side. In addition, scapular protraction, retraction, elevation and depression, that were lacking in the group reported by Damron et al,<sup>5</sup> all were functioning in the patients in the current study.

Reconstruction with a constrained total scapula prosthesis is preferred by the current authors because it restores most of the bony architecture necessary for reconstructing the normal muscle force couples of the scapulothoracic and glenohumeral mechanisms, both of which are important for optimal shoulder girdle abduction and upper extremity stabilization<sup>16</sup> (Table 2). Usually during resection of most scapular sarcomas and sarcomas arising from

**TABLE 2. Comparison of Nonanatomic and Anatomic Reconstructions**

Outcome	Nonanatomic	Anatomic
Stability	Poor	Good to excellent
Cosmesis	Poor	Good
External rotation	None	Neutral to $-10^{\circ}$
Abduction	$0^{\circ}$ – $10^{\circ}$	$35^{\circ}$ – $60^{\circ}$
Upper extremity strength	Poor	Good
Complications (hardware failure, infection, skin erosion, traction neurapraxia)	Substantial	Few

the rotator cuff, most of the muscles necessary for reconstructing scapulothoracic and glenohumeral mechanisms can be preserved, namely the deltoid, trapezius, rhomboids, latissimus, and serratus anterior muscles. The rotator cuff, however, an essential component of the glenohumeral mechanism, usually is resected and its function must be restored during the reconstruction. The humeral head usually is stabilized actively in the glenoid by the rotator cuff that converts the glenohumeral joint into a fixed fulcrum and enables angular acceleration of the joint, powered by the deltoid muscle. The constrained glenoid, by providing a fixed fulcrum, attempts to passively restore the normal inferior and medial force provided by the rotator cuff that prevents superior humeral translation with deltoid contraction. Therefore, the superiorly directed force vector of the deltoid may be more efficiently converted into an angular acceleration (abduction) of the glenohumeral joint (Fig 6). An improvement in abduction and stability of the glenohumeral joint combined with active scapulothoracic motion enhances global shoulder girdle abduction, strength, and stability.

The current authors describe a new, constrained total scapular prosthesis and surgical technique termed anatomic reconstruction after modified, Tikhoff-Linberg shoulder girdle resection. The locking mechanism provides a secure attachment for the proximal humerus prosthesis and partially substitutes for the resected rotator cuff muscles and glenohumeral joint capsule. This system, which uses all remaining periscapular muscles, restores glenohumeral and scapulothoracic mechanisms, and poten-

tially improves active glenohumeral motion, shoulder girdle stability, and strength for optimal upper extremity function. The locking design also facilitates intraoperative attachment of the proximal humerus to the scapula, thereby easing surgical reconstruction and reducing the risk of future dissociation. However, the results presented in the current study are preliminary, and additional followup is warranted. With the increasing use of induction chemotherapy, it is likely that more high-grade sarcomas involving the scapula will be resectable with preservation of the necessary musculature to facilitate reconstruction with this anatomic approach.

#### References

- Asavamongkolkul A, Eckardt JJ, Eilber FR, et al: Endoprosthetic reconstruction for malignant upper extremity tumors. *Clin Orthop* 360:207–220, 1999.
- Badhwar R: Reconstruction following limb-sparing en bloc resection of the shoulder girdle- Tikhoff-Linberg procedure. *Ind J Cancer* 27:31–37, 1990.
- Biagini R, Capanna R, Van Horn JR, et al: Scapulectomy: Report on the results of 28 patients. *Acta Orthop Belg* 42:732–742, 1986.
- Capanna R, Van Horn JR, Biagini R, et al: The Tikhoff-Linberg procedure for bone tumors of the proximal humerus: The classical “extensive” technique versus a modified “transglenoid” resection. *Arch Orthop Trauma Surg* 109:63–57, 1990.
- Damron TA, Rock MG, O’Connor MI, et al: Functional laboratory assessment after oncologic shoulder joint resections. *Clin Orthop* 348:124–134, 1998.
- Enneking WF, Dunham W, Gebhardt MC, et al: A system for the functional evaluation of reconstructive procedures after surgical treatment of tumors of the musculoskeletal system. *Clin Orthop* 286:241–246, 1993.
- Francis KC, Worcester JN: Radical resection for tumors of the shoulder with preservation of a functional extremity. *J Bone Joint Surg* 44A:1423–1430, 1962.

8. Ham SJ, Hoekstra HJ, Eisma WH, Koops HS, Oldhoff J: The Tikhoff-Linberg procedure in the treatment of sarcomas of the shoulder girdle. *J Surg Oncol* 53:71-77, 1993.
9. Kumar VP, Satku SK, Mitra AK, Pho RWH: Function following limb-salvage for primary tumors of the shoulder girdle. *Acta Orthop Scand* 65:55-61, 1994.
10. Lindberg BE: Interscapulo-thoracic resection for malignant tumors of the shoulder girdle region. *J Bone Joint Surg* 10:344-349, 1928.
11. Malawer MM: Tumors of the shoulder girdle: Technique of resection and description of a surgical classification. *Orthop Clin North Am* 22:27-35, 1991.
12. Marcove RC, Lewis MM, Huvos AG: En bloc upper humeral interscapulo-thoracic resection. *Clin Orthop* 124:219-228, 1977.
13. O'Connor MI, Sim FH, Chao EY: Limb salvage for neoplasms of the shoulder girdle: Intermediate reconstructive and functional results. *J Bone Joint Surg* 78A:1872-1888, 1996.
14. Papaioannou AN, Francis KC: Scapulectomy for the treatment of primary malignant tumors of the scapula. *Clin Orthop* 41:125-132, 1965.
15. Voggenreiter G, Assenmacher S, Schmit-Neurenburg KP: Tikhoff-Linberg procedure for bone and soft tissue tumors of the shoulder girdle. *Arch Surg* 134:252-257, 1999.
16. Ward B, McGarvey C, Loetz M: Excellent shoulder function is attainable after partial or total scapulectomy. *Arch Surg* 125:537-542, 1990.



**Unauthorized Use  
Prohibited**