

James S. Jelinek, MD  
Mark D. Murphey, MD  
James A. Welker, DO  
Robert M. Henshaw, MD  
Mark J. Kransdorf, MD  
Barry M. Shmookler, MD  
Martin M. Malawer, MD

**Index terms:**

Bone neoplasms, 40.32  
Bones, biopsy, 40.1261  
Giant cell tumor, 40.3182  
Lymphoma, 40.34  
Osteosarcoma, 40.32  
Sarcoma, 40.3211

**Published online before print**

10.1148/radiol.2233011050  
**Radiology 2002; 223:731-737**

<sup>1</sup> From the Depts of Radiology (J.S.J.) and Pathology (B.M.S.), Washington Hospital Ctr, 110 Irving St NW, Washington, DC 20010; Dept of Orthopedic Oncology, Washington Cancer Institute, Washington Hospital Ctr, Washington, DC (J.S.J., J.A.W., R.M.H., M.M.M.); Dept of Radiologic Pathology, Armed Forces Institute of Pathology, Washington, DC (M.D.M.); Dept of Radiology, Univ of Maryland Med Systems, Baltimore (M.D.M.); Dept of Radiology and Nuclear Med, Uniformed Services Univ of Health Sciences, Bethesda, Md (M.D.M.); Dept of Radiology, Mayo Clinic, Jacksonville, Fla (M.J.K.); and Dept of Orthopedic Surgery, George Washington Univ, Washington, DC (M.M.M.). From the 1999 RSNA scientific assembly. Received Jun 14, 2001; revision requested Aug 8; revision received Oct 1; accepted Nov 12. **Address correspondence to** J.S.J. (e-mail: JSJ2@medstar.net).

© RSNA, 2002

**Author contributions:**

Guarantor of integrity of entire study, J.S.J.; study concepts, J.S.J., M.J.K., J.A.W.; study design, J.S.J., M.D.M., J.A.W.; literature research, J.A.W., J.S.J.; clinical studies, J.S.J., M.D.M.; data acquisition, J.S.J., B.M.S., R.M.H., M.M.M.; data analysis/interpretation, J.S.J., B.M.S.; statistical analysis, J.S.J., J.A.W.; manuscript preparation, J.S.J., M.D.M., M.J.K.; manuscript definition of intellectual content, J.S.J., J.A.W.; manuscript editing, J.S.J., M.D.M.; manuscript revision/review, all authors; manuscript final version approval, J.S.J., J.A.W., M.D.M., M.J.K.

# Diagnosis of Primary Bone Tumors with Image-guided Percutaneous Biopsy: Experience with 110 Tumors<sup>1</sup>

**PURPOSE:** To determine the diagnostic accuracy of image-guided percutaneous biopsy in 110 primary bone tumors of varying internal compositions.

**MATERIALS AND METHODS:** One hundred ten consecutive patients with primary bone tumors underwent biopsy with computed tomography (CT) or fluoroscopy. Ninety-one patients underwent surgical follow-up and 19 received medical treatment and underwent subsequent imaging studies. Final analysis of bone biopsy results included tumor type, malignancy, final tumor grade, biopsy complications, and effect on eventual treatment outcome.

**RESULTS:** Seventy-seven tumors were malignant and 33 were benign. Most common tumors at biopsy were osteosarcoma ( $n = 20$ ), lymphoma ( $n = 18$ ), chondrosarcoma ( $n = 16$ ), and giant cell tumor ( $n = 16$ ). Correct final diagnosis was attained in 97 (88%) patients. Sixty-three lesions were solid nonsclerotic; 26, sclerotic; and 21, lytic with cystic centers containing internal areas of fluid, hemorrhage, or necrosis. In six of 21 lesions with a predominant cystic internal composition, problems occurred in determining a final diagnosis. In 13 patients, definite correct diagnosis was not obtained with initial percutaneous bone biopsy. Of these patients, benign bone tumors were better defined with surgical specimens in seven, a diagnosis of malignancy was changed to that of another malignancy in four, and the diagnosis was changed from benign to malignant in two. Nine patients underwent open surgical biopsy. Seven of the difficult cases were of cystic tumors with hemorrhagic fluid levels visible at CT or magnetic resonance imaging. The only complication was a small hematoma.

**CONCLUSION:** Percutaneous biopsy of primary bone tumors is safe and accurate for diagnosis and grade of specific tumor. In cases with nondiagnostic biopsy, open-procedure biopsy is likely to be associated with similar diagnostic difficulties.

© RSNA, 2002

Image-directed percutaneous biopsy is becoming an increasingly accepted modality for initial biopsy in most musculoskeletal tumors. Despite well-documented specificity and sensitivity (1-4), there has been continued reluctance on the part of orthopedic oncologists to accept this technique as the modality of choice for the initial biopsy in primary bone tumors. Detractors of percutaneous needle biopsy suggest that sufficient material cannot be obtained to ensure an accurate diagnosis, particularly in patients with sclerotic bone lesions (5-9). The purpose of our study was to determine the diagnostic accuracy of image-guided percutaneous biopsy in 110 primary bone tumors of varying internal compositions.

## MATERIALS AND METHODS

### Study Data

We retrospectively reviewed the records of 110 consecutive patients in whom primary bone tumors were proved by means of biopsy results who were initially referred for percutaneous image-guided biopsy. All patients underwent evaluation at Washing-

ton Cancer Institute, Washington Hospital Center, Washington, DC, and all biopsies were performed by an experienced musculoskeletal radiologist (J.S.J.). Decision to perform biopsy was made by the referring senior orthopedic oncologist and was, in general, limited to those patients in whom results would alter clinical treatment. For example, biopsy was not performed in patients with benign-appearing lesions that would usually receive definitive treatment, typically curettage and bone grafting, whereas biopsy was performed in patients who were suspected of having malignancies that possibly required neoadjuvant chemotherapy.

Because this was a retrospective study of primary bone tumor biopsy results, patients who eventually received a diagnosis of metastatic lesions, infection, inflammatory reactive lesions, or recurrent tumor were excluded from this study. One hundred ten consecutive patients (66 female patients, 44 male patients; mean age, 38 years; age range, 8–84 years) who were referred for percutaneous bone biopsy and had received a diagnosis of primary bone tumor during the 8 years between January 1992 and December 1999 were included. Diagnosis by means of percutaneous bone biopsy results was confirmed surgically by means of definitive resection in 91 patients. The remaining 19 patients were treated nonsurgically, and diagnosis by means of percutaneous bone biopsy results was confirmed by means of an unchanged image appearance for more than 2 years in benign lesions and of healing after chemotherapy and/or radiation therapy in malignant lesions (myeloma, lymphoma).

All biopsy material was evaluated by a surgical pathologist (B.M.S.) with extensive musculoskeletal experience. Although cytopathologists were available to evaluate the initial specimens, the final diagnosis was always made by the surgical pathologist with musculoskeletal experience. When appropriate, the Department of Orthopedic Pathology, Armed Forces Institute of Pathology, Washington, DC, was consulted for confirmatory diagnosis. A definite diagnosis was considered one in which there was conclusive analysis of tumor type and, if malignant, tumor grade.

Institutional review board approval and informed consent were not required for this study, because data used did not breach patient confidentiality, and no identifying data were disclosed.

### Biopsy Technique

All biopsies were planned in consultation with the referring orthopedic sur-

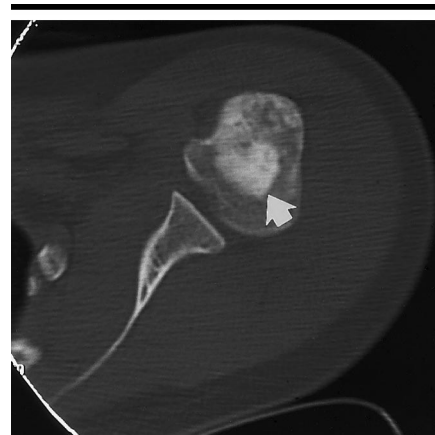geon (M.M.M., R.M.H.), and needle pathway was decided on the basis of the expected definitive treatment to avoid intercompartmental contamination, to minimize the amount of biopsy tract to be removed at the time of definitive surgery, and to avoid neurovascular structures. Percutaneous biopsy was performed with computed tomographic (CT) guidance in 85 patients and with fluoroscopic guidance in 25 patients.

Use of CT versus fluoroscopy was determined on the basis of three factors. First, the size of the lesion was assessed. Biopsies in small lesions were performed with CT guidance. Large lesions were potentially considered for biopsy with fluoroscopic guidance. Second, the presumed plan for definitive resection incision and proximity of the incision to the neurovascular bundle was an additional consideration. Anytime the neurovascular bundle could be potentially contaminated, CT was preferred. Finally, the general availability of the angiographic suites versus that of CT was considered. At Washington Cancer Institute, the CT scanners were more likely to be available for percutaneous bone biopsy.

All patients were sedated with intravenous administration of midazolam hydrochloride (0.5–4.0 mg) and fentanyl citrate (25–200  $\mu$ g), and vital signs, pulse oximetry, and automated blood pressure were monitored continuously. All biopsies were performed with a cytopathologist to ensure adequacy of the specimen quality, but the cytopathologist did not sign the final surgical pathology report. The biopsy continued until the cytopathologist was satisfied with the adequacy of the amount of viable tissue. In most patients, an additional one or two cores were obtained in addition to this amount. An aspiration technique similar to that previously described (10,11) was used. While cytologic aspiration results may be diagnostic without cores (10, 12,13), in all of the patients in our study both cytologic aspirations and tissue cores were obtained. The number of passes varied as required for diagnosis but ranged between three and 10 cores (average, 5.5 cores). On the basis of the internal composition of the lesion, biopsy technique was adapted to the specific type of lesion being evaluated.

### Sclerotic Lesions

There were 26 patients with a sclerotic tumor. A sclerotic lesion was defined as a lesion in which greater than 50% of its internal composition was equal to the

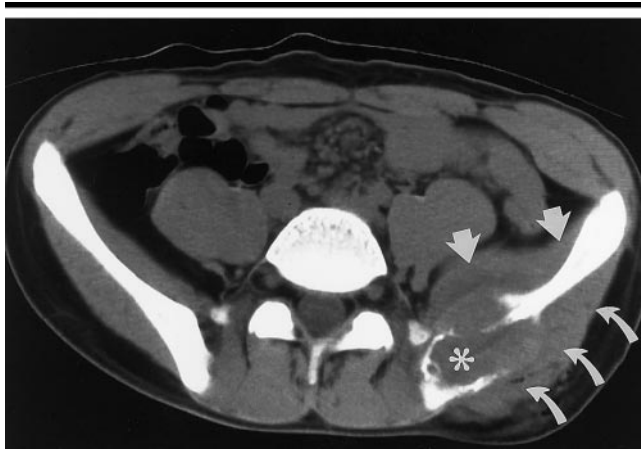


**Figure 1.** Transverse CT image of the left shoulder obtained in a 16-year-old adolescent girl shows a small sclerotic osteosarcoma (arrow) of the proximal humerus. Note that attenuation of the lesion is equal to or greater than that of the adjacent bone cortex. Osteosarcoma was proved with biopsy results and was surgically resected.

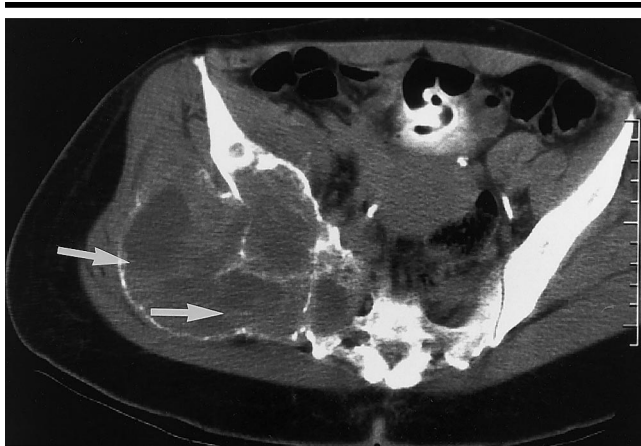attenuation of bone on the basis of CT images, when available; otherwise, this was determined on the basis of findings with plain film radiographs (Fig 1). A large 7–14-gauge bone biopsy needle (Temno Bone Needles; Bauer Medical, Clearwater, Fla) and a bone needle (Ostycut; AngioMed, Berlin, Germany) were used. The cortex around the lesions was penetrated by using the needle tip with manual pressure or gentle tapping with an orthopedic hammer. After the initial core was successfully obtained, subsequent cores were easily obtained through or adjacent to the same biopsy track. Fine-needle aspiration was also performed in sclerotic lesions by placing an 18-gauge needle through the larger-bore needle. Despite the fact that the bones were extremely hard, it was possible to obtain tiny spicules of bone and/or blood in the middle of these lesions after they had been traversed with a larger-bore needle.

### Solid Nonsclerotic Lesions

There were 63 patients with solid nonsclerotic lesions. A solid lesion was defined as a lesion in which greater than 50% of its internal composition was soft-tissue attenuation (Fig 2). Biopsy in these lesions was typically performed with a 12–16-gauge Ostycut or Temno bone needle, and specimens were easily obtained. Little difficulty was encountered in obtaining solid pathologic cores with these tumor types. Coaxial biopsy, such as that performed with an 18-gauge nee-



**Figure 2.** Transverse CT image of the upper pelvis obtained in a 16-year-old adolescent boy shows a nonsclerotic lytic lesion (\*) of the left iliac bone, with predominant soft-tissue attenuation. There is involvement of the iliac bone and extension into the gluteal muscle (curved arrows) and into the iliac muscle (straight arrows). Ewing sarcoma was proved with biopsy results.



**Figure 3.** Transverse contrast material-enhanced CT image of the middle of the pelvis obtained in a 45-year-old woman with a newly diagnosed 6-cm renal cell carcinoma and a mass in the right hip shows a cystic tumor. The CT scan shows a large cystic lesion of the right iliac bone, with multiple small hemorrhagic fluid levels (arrows). Initial percutaneous biopsy results showed nonspecific malignant cells. Frozen section analysis results at the time of surgery were also positive for malignancy but not diagnostic of osteosarcoma. Final pathologic evaluation after resection of the gross specimen showed telangiectatic osteosarcoma.

dle inserted through a 12- or 16-gauge needle, with final cores being obtained with the larger needle size, was frequently used in this group.

### Cystic Lesions

There were 21 patients with tumors that showed greater than 50% of the internal composition to contain central fluid, blood, or fluid levels at CT or magnetic resonance (MR) imaging (Fig 3). "Cystic" is a descriptive term for these

tumors that contained predominantly fluid and blood. These tumors were not cysts in the true pathologic sense of having a thin, regular, epithelialized wall. These tumors were the hardest in which to obtain solid core tissue, as they were predominantly composed of fluid, blood, or nonsolid necrotic material.

Two different techniques were typically used to obtain pathologic samples. After the initial overlying cortex was punctured and a safe pathway was obtained, multiple

passes were made with a 14–18-gauge biopsy gun (ASAP Biopsy System Gun; Boston Scientific, Natick, Mass). If this technique was not successful, then the other technique was to use an Ostycut bone needle that was passed through a larger opening into the bone, if any overlying cortical bone remained, to allow "minicuretting" (ie, scraping the inside of the bone lesion) of the perimeter of the bone tumor. This required a considerably larger entrance hole, as from a 7- or 9-gauge bone needle, to allow movement within the cortical hole for a 14–16-gauge Ostycut bone needle.

### Pathologic Analysis and Follow-up

Final analysis of bone biopsy results included type of tumor, presence of malignancy, final grade of tumor, complications of biopsy, and effect on the eventual treatment outcome. The final analysis of tumor type, malignancy, and tumor grade were determined by the surgical pathologist (B.M.S.) with musculoskeletal experience. The effect on eventual tumor treatment was assessed by the senior orthopedic oncologist (M.M.M., R.M.H.) on the basis of his expected protocol of treatment. For example, benign or low-grade malignant lesions typically would be treated by means of curettage, freezing, and packing with methyl methacrylate or by means of bone grafting. More aggressive malignant tumors typically would be treated by means of neoadjuvant chemotherapy and/or radiation therapy prior to definitive resection.

Follow-up in all patients was performed by members of the Department of Orthopedic Oncology, Washington Cancer Institute, through their computerized database and patient follow-up information. Cases of all patients ( $n = 91$ ) who underwent surgery were discussed at a preoperative surgical conference. Cases of all malignant tumors ( $n = 77$ ) were discussed at a multidisciplinary orthopedic oncology conference. In 91 patients, tumor diagnosis was reviewed after surgical resection. In the 19 patients who did not undergo surgical excision, a minimum of 2 years of clinical and radiologic follow-up substituted as the reference standard for final diagnosis. The diagnoses in these patients who received medical treatment and underwent follow-up included solitary lymphoma of bone ( $n = 8$ ), plasmacytoma ( $n = 3$ ), granulocytic sarcoma ( $n = 2$ ), hemanangioma ( $n = 2$ ), fibrous dysplasia ( $n = 1$ ), Ewing sarcoma ( $n = 1$ ), enchondroma ( $n = 1$ ), and nonossifying fibroma ( $n = 1$ ).

Benign lesions showed no changes during follow-up. Malignant lesions showed sclerotic healing without progression; patients eventually undergoing surgical treatment were considered to be in the surgical confirmation category.

## RESULTS

### Clinical Data

A conclusive correct biopsy result was obtained in 97 (88%) of 110 patients. Four diagnoses accounted for 64% of all lesions: osteosarcoma ( $n = 20$ ), lymphoma ( $n = 18$ ), chondrosarcoma ( $n = 16$ ), and giant cell tumor ( $n = 16$ ) (Table 1).

In 13 patients, a misdiagnosis was obtained by means of percutaneous bone biopsy (Table 2). Of these 13, seven had a nonspecific diagnosis of a benign tumor that was accurately diagnosed at resection. These included a giant cell tumor with a large aneurysmal bone cyst component, two aneurysmal bone cysts, two nonossifying fibromas, and two desmoplastic fibromas. In four patients who had a malignant bone tumor, the diagnosis was changed from one malignant tumor type to another. In the four patients who had a change in malignant tumor type, the altered diagnoses included changes from a leiomyosarcoma to a dedifferentiated chondrosarcoma, from a malignancy not otherwise specified to osteosarcoma, from a malignant vascular neoplasm not otherwise specified to angiosarcoma, and from a sarcoma not otherwise specified to fibrosarcoma.

The two most important misdiagnoses were changes from benign to malignant tumors. These two diagnoses included a tumor with hemorrhage and fluid levels at both MR imaging and CT, with the diagnosis being changed from a giant cell tumor to telangiectatic osteosarcoma, and a fibrous spindle cell tumor, with the diagnosis being changed from benign tumor to fibrosarcoma. Both of these final diagnoses were also missed at frozen section analysis at initial surgery. Hence, there was a 98% (108 of 110) accuracy for differentiating benign from malignant tumor.

In eight (7%) of 110 patients, the eventual final grade of the tumor was changed, including the two tumor grades that were changed from benign to malignant. The other grade changes included two chondrosarcomas and two fibrosarcomas that were initially graded as low to intermediate, and final diagnosis showed

**TABLE 1**  
Consistency of Tumor Types

Tumor	Total	Sclerotic	Solid	Cystic
Malignant	77	22	46	9
Osteosarcoma	20	15	2	3
Lymphoma	18	4	14	0
Chondrosarcoma	16	3	13	0
Ewing sarcoma, primitive neuroectodermal tumor	6	0	6	0
Plasmacytoma	6	0	1	5
Other	11	0	10	1
Benign	33	4	17	12
Giant cell	16	0	10	6
Aneurysmal bone cyst	3	0	0	3
Fibrous dysplasia	3	2	0	1
Chondroblastoma	3	0	2	1
Other	8	2	5	1

several small foci of high-grade tumor. Two tumors ordinarily considered benign developed clear evidence of metastasis, and these included one case each of a giant cell tumor and a chondroblastoma, both of which eventually developed widespread pulmonary metastasis. The patient with chondroblastoma eventually died of metastatic disease. Pathologic material from both of these tumors was reviewed with staff at the Armed Forces Institute of Pathology after initial surgery, and the tumors were diagnosed as benign with atypical and worrisome features. Since these benign tumors developed metastatic disease, they were considered high-grade tumors.

### Open Surgical Biopsy

In nine (8%) of 110 patients, open surgical biopsy was performed owing to uncertainty of the diagnosis after percutaneous needle biopsy. Of these nine patients, five also eventually had an incorrect definitive diagnosis. In the other four, the open surgical biopsy results helped confirm the correct diagnosis at percutaneous needle biopsy. Tumors requiring open surgical biopsy included three osteosarcomas, three giant cell tumors, one chondroblastoma, one aneurysmal bone cyst, and one fibrosarcoma. In seven of these nine patients, lesions were predominantly cystic, and all three of the osteosarcomas were of the telangiectatic type. Two of the giant cell tumors and the aneurysmal bone cyst were nearly completely cystic, and at CT or MR imaging, they contained multiple fluid levels caused by internal hemorrhage.

### Major Diagnostic Errors

Major diagnostic errors occurred in three (3%) of 110 patients and would

have changed patient care. In all three patients, the same errors occurred at the time of frozen section analysis at open surgical resection of the tumor, and the final diagnosis in these patients was not determined until several days after surgical resection. These major errors included a diagnosis of giant cell tumor with prominent aneurysmal bone cyst-like fluid levels at percutaneous needle biopsy; the diagnosis was changed to telangiectatic osteosarcoma. At presentation, a patient with a 6-cm renal cell carcinoma had a painful 12-cm lytic bubbly cystic lesion of the iliac bone with multiple fluid levels (Fig 3). The diagnosis was changed from high-grade malignant metastatic tumor to telangiectatic osteosarcoma. A third tumor that was initially believed to represent a benign spindle cell fibrous tumor eventually was determined to be an intermediate-grade fibrosarcoma.

### Complications

There were no vascular or nerve injuries. There were no tumor recurrences along any biopsy tracts. A small hematoma that was treated conservatively was the only complication.

### Assessment according to Type of Lesion

*Sclerotic lesions.*—There were 26 sclerotic lesions (Table 1, Fig 1). These included 15 osteosarcomas, four lymphomas, three chondrosarcomas, and four benign lesions (two fibrous dysplasia lesions, one osteoblastoma, and one enchondroma). A majority of enchondromas and fibrous dysplasia lesions are typically not sclerotic; however, the imaging features in these patients showed a considerable amount of dense mineralization and/or ossification that prompted

**TABLE 2**  
**Misdiagnosis with Needle Biopsy**

No. of Patients	Diagnosis with Needle Biopsy	Tumor Consistency	Diagnosis with Frozen Section Analysis	Final Diagnosis
2	Benign tumor, not otherwise specified	Cystic	Aneurysmal bone cyst	Aneurysmal bone cyst
2	Benign spindle cell tumor, not otherwise specified	Solid	Benign spindle cell tumor	Desmoplastic fibroma
2	Benign tumor, not otherwise specified	1 solid, 1 cystic	Nonossifying fibroma	Nonossifying fibroma
1	Benign spindle cell tumor, not otherwise specified	Solid	Benign spindle cell tumor	Giant cell tumor
1	Leiomyosarcoma	Solid	High-grade malignant tumor	Chondrosarcoma
1	Sarcoma	Solid	Sarcoma	Fibrosarcoma
1	Benign spindle cell tumor	Solid	Spindle cell tumor, nonossifying fibroma	Fibrosarcoma
1	Giant cell tumor	Cystic	Giant cell tumor	Osteosarcoma
1	Malignant tumor, possible metastasis	Cystic	Malignant	Osteosarcoma
1	Malignant vascular neoplasm	Cystic	Angiosarcoma	Angiosarcoma

**TABLE 3**  
**Results at Biopsy for Diagnosis and Determination of Malignancy**

Tumor Consistency	Total No. of Tumors	Tumor Diagnosis			Determination of Malignancy	
		Exact	Incorrect or Nondiagnostic	Accuracy (%)*	Correct	Accuracy (%)†
Sclerotic	26	26	0	100	26	100
Solid	63	56	7	89	62	98
Cystic	21	15	6	71	20	95
Overall	110	97	13	88	108	98

\* Numbers in columns 2 and 3 were used to calculate percentages.

† Numbers in columns 2 and 6 were used to calculate percentages.

percutaneous biopsy. An adequate number of samples were removed from all sclerotic lesions at the time of percutaneous biopsy. None of the sclerotic lesions caused diagnostic dilemmas or required open surgical biopsy. After initial penetration of the cortex with a large-bore needle (7–14 gauge), tumor samples were progressively easier to obtain. During this study, progressively larger core needles were used, because with them it was easier to penetrate cortical bone, but without an increase in complications. Larger-volume tumor samples were obtained with larger core needles.

**Solid nonsclerotic lytic lesions.**—A majority of the lesions ( $n = 63$ ) were tumors that were neither predominantly matrix forming (sclerotic) nor predominantly cystic or cavitory (Table 1, Fig 2). Overall for these tumors, there was relative ease in obtaining acceptable quantities of core material. Only two of these patients required subsequent open surgical biopsy, predominantly because of the unusual appearance of the specimens pathologically. One of these represented a spindle cell tumor of the sacrum, which was determined to be a giant cell tumor after consultation with staff at the Armed

Forces Institute of Pathology. The second lesion was a spindle cell fibrous tumor that was eventually diagnosed as an intermediate-grade fibrosarcoma.

**Cystic lesions.**—Twenty-one lesions were predominantly cystic and were filled with blood or necrotic material or demonstrated cyst formation, as identified at CT or MR imaging (Table 1, Fig 3). These lesions consisted of little solid material, and 15 (71%) had hemorrhage with fluid levels at CT or MR imaging. In these lesions, accuracy for benign versus malignant diagnosis and for exact tumor diagnosis was lowest (Tables 2, 3). These cystic lesions accounted for two of the three major diagnostic errors. Technically, in these tumors difficulty in obtaining adequate quantities of diagnostic tumor material was greatest. With perimeter minicuretting of the bone tumor, a larger volume of tumor specimen was obtained than was obtained from the middle of the lesion with a biopsy gun. Fluid or blood samples obtained from the center of the lesion at aspiration did not contain adequate amounts of diagnostic tumor cells, and, therefore, aspiration of fluid or blood alone should be considered a worthless diagnostic procedure.

## DISCUSSION

Percutaneous techniques in which fluoroscopy, CT, ultrasonography and, in some centers, MR imaging, are used have virtually replaced the requirement for open surgical biopsy in obtaining samples of carcinoma of the chest, abdomen, and pelvis and of some soft-tissue tumors (14–21). Widespread acceptance of using percutaneous biopsy in the initial assessment of primary bone tumors has been slowly accepted by orthopedic surgeons (8,9,22,23). Results of this study and of others (1,22,24,25) demonstrate that, in carefully controlled situations in which the musculoskeletal radiologist works in a team approach with the orthopedic oncologist and orthopedic pathologist, the results of percutaneous biopsy can be extremely effective and accurate.

As has been demonstrated in previous studies (22–24), the improvement in overall cost-effectiveness of percutaneous biopsy, compared with that of open biopsy, is three- to sevenfold. Additional potential advantages of percutaneous needle biopsy include biopsy of various tumor quadrants, a lower complication rate, preoperative planning, ability to more rapidly begin neoadjuvant chemotherapy and radiation therapy, and a more limited biopsy tract to be removed at the time of definitive wide or radical excision (8,9,19,26). Many biopsies in malignant tumors were performed to obtain the diagnosis before administration of neoadjuvant chemotherapy. With a definitive diagnosis, neoadjuvant chemotherapy or radiation therapy can be started the day after core-needle biopsy. After a surgical approach, a delay of 10 days to 3 weeks is required to allow wound healing and prevention of infection and bleeding (8,9,17,26).

A benefit of controlled radiologically guided biopsy is that a cytopathologist can immediately determine the adequacy of the specimen (14,15,27,28). If the cytopathologist determines that the initial material is inadequate, the biopsy can continue with more passes by using different needles until enough viable tissue has been obtained for diagnosis. In most cases, biopsy may need to be performed in an entirely different area of the tumor determined at CT or MR imaging to identify diagnostic cells. In our experience, the single greatest error is failure to obtain enough core biopsy material to satisfy both the cytopathologists and the surgical pathologists.

An additional benefit of CT-guided biopsy is that some tumors, such as parosteal osteosarcoma, may have foci that are of a higher grade than other regions (29). Typically, in parosteal osteosarcoma, the less mineralized area is of a higher grade, and it can be specifically targeted with CT for biopsy (25,29).

Strict adherence to orthopedic oncologic consultation and compartmental anatomy is mandatory to avoid complications of percutaneous biopsy for future surgery (27,30). Anderson et al (30) discussed the relevance of compartmental anatomy in biopsy performed in musculoskeletal tumors. The information in their article is necessary to musculoskeletal radiologists performing primary bone biopsy if they are not aware of the compartmental anatomy and the surgical approaches. In addition, consultation with orthopedic oncologists is invaluable in the planning of the procedure. In previous reports, as many as 25% of biopsies in musculoskeletal sarcoma were performed inappropriately, which resulted in alteration of surgical treatment in 10% (7–9,26) and limb amputation in 3% (7–9) of patients.

The overall complication rate (1% [1 of 110]) in our study was extremely low. Open biopsy may result in delayed wound healing and infection. In contrast, percutaneous needle biopsy does not require time for wound healing and offers a substantially lower risk of infection (19,26). Orthopedic open surgical complication rates are commonly in the 2%–20% range (8,9,20,26), with the most common complications including infection, hematoma, and nerve injury (8,9,20,26). In this series, there was one small hematoma that was adequately treated conservatively. Nerve injury was not encountered in this series, but care was always taken to identify the neurovascular bundle. Because a majority of these biopsies were performed with CT

guidance, the nerve pathways could be identified easily. Therefore, whenever a neurovascular bundle might be near the intended pathway of the biopsy, CT guidance was used. In large lesions in which the neurovascular bundle is not near the biopsy tract, fluoroscopic guidance can be used just as easily.

Results from our series demonstrated that when an accurate diagnosis is difficult to obtain by means of needle biopsy, it is equally difficult to obtain by means of open biopsy. Tumors with a difficult diagnosis were a diagnostic dilemma after both needle and open surgical biopsy. Perhaps with the knowledge from percutaneous biopsy that diagnosis may be difficult, open biopsy may be performed more carefully to maximize the amount of tissue obtained and limit the scope of the procedure to obtaining diagnostic material. In addition, in institutions in which a dedicated musculoskeletal pathologist is not always available, it would be appropriate to make arrangements for one to be present to review these cases at the time of surgery.

Little has been discussed about the internal composition of bone lesions on the basis of radiographs, CT scans, and MR images and the decision to perform percutaneous needle biopsy (5,8,31). The internal composition of a tumor is an important factor in determining which needle to use and whether percutaneous biopsy may be successful. With use of modern needles with sharp cutting edges, or larger-size 7–14-gauge needles, and orthopedic hammers and drills, biopsy of sclerotic tumors is no longer difficult (31). In the past, obtaining a diagnostic sample of sclerotic bone tumors at biopsy was a major problem (8,17,26). In our study, no patient with a sclerotic lesion had nondiagnostic biopsy results.

Biopsy is usually easy in solid nonsclerotic lesions, and adequate pathologic material is obtained. Nonetheless, unusual tumors, such as desmoplastic fibromas, may be difficult to diagnose even with adequate core-needle biopsy material. Unusual histologic features may cause diagnosis of any primary bone tumor to be difficult. Even within a single lesion, there can be mixed areas with cystic features or areas of sclerosis. It is imperative to perform biopsy carefully in the various sectors of the tumor to avoid sampling error. For tumor types with unusual histologic patterns, the surgical pathologist will want to know whether these unusual patterns were present throughout the whole lesion or whether they were confined to small areas of the

tumor. When biopsy is performed in multiple sectors, multiple cores must be obtained from these areas. In many cases in this study, eight to 10 cores were obtained.

Cystic bone tumors containing substantial amounts of fluid, blood, or necrotic material are most likely to create difficulty in obtaining adequate tissue cores and can result in a pathologic dilemma. The presence of prominent blood or fluid levels seen at MR imaging or CT should alert both the musculoskeletal radiologist and the orthopedic oncologist that tumor diagnosis may be challenging whether open or percutaneous biopsy is performed (5). The descriptive term “cystic” again has been used purely to describe those lesions that are predominantly filled with fluid or blood; it is not meant to imply that these lesions, in fact, contained a true epithelial lining.

A diligent search for more solid regions or areas of enhancement at MR imaging or CT can be vital in directing the biopsy to viable regions harboring diagnostic tissue. The areas of fluid levels invariably contain nondiagnostic tissue. Six (46%) of 13 misdiagnosed tumors had a cystic internal composition, and yet it was least common to perform biopsy in cystic tumors. Curettage of the wall of the lesion in these cystic bone lesions improves diagnostic yield. Aspiration of fluid or blood from these lesions is of no diagnostic utility.

A multidisciplinary approach with a team of experienced orthopedic oncologists, musculoskeletal radiologists, and musculoskeletal pathologists minimizes the number of inappropriate bone biopsies and allows for a higher diagnostic yield at bone biopsy. At Washington Cancer Institute, the initial technique to obtain diagnostic tissue for all primary bone tumors for which biopsy results would change the clinical treatment is a percutaneous rather than an open surgical approach. This algorithm results in a lower complication rate and cost savings, and yet it maintains a high degree of diagnostic accuracy.

The high degree of diagnostic accuracy (88% [97 of 110 cases] for correct histologic diagnosis and 98% [108 of 110 cases] for determination of benign vs malignant tumors) compares favorably with that in several other articles (1,24,25). In the study of Fraser-Hill et al (1,24), an accuracy of only 83% was determined in identifying musculoskeletal tumors, both bone and soft tissue, and Yao et al (25) also reported an accuracy of 83% for the

histologic type of musculoskeletal tumors.

Reasons for better results include that a senior orthopedic oncologist (M.M.M., R.M.H.) was involved in the decision making, and, hence, biopsy was performed in relatively few benign lesions. Also, the same musculoskeletal radiologist (J.S.J.) and surgical pathologist (B.M.S.) were involved in all of the cases, which improved both quality and quantity of the specimens and the degree of competence of the surgical pathologist in rendering a final opinion. In addition, as noted in the Materials and Methods section, a cytopathologist was always available to assess the fine-needle aspirate to ensure that viable tumor cells were being obtained. In essence, this method provides a "frozen section analysis" diagnosis. Unless the pathologist can see viable cells in which to use special stains, biopsy is continued until diagnostic material is obtained. Previous authors (1,24,25) performed biopsy and obtained a small number of aspirates and cores without the definitive knowledge that they had obtained diagnostic tissue before terminating the procedure.

Finally, unlike the authors of prior studies (1,24,25), we used intravenous sedation in all patients during all primary bone tumor biopsies so that greater numbers of cores and larger-gauge cores could be obtained. When a patient experiences substantial discomfort, rather than being either asleep or completely at ease, it is more likely that the physician performing the procedure will terminate the biopsy early. There is a substantially greater difference in pain experienced between patients who undergo bone biopsy without conscious sedation and those who undergo bone biopsy with conscious sedation (32).

In conclusion, the results of this study demonstrate that a high degree of accuracy in diagnosis and effectiveness can be achieved with percutaneous bone biopsy in primary bone tumors; as a result, open biopsy may be precluded in a majority of cases. A careful assessment of tumor internal composition may be important in the type of needle used for biopsy. High diagnostic accuracy was achieved with biopsy in both sclerotic and solid nonsclerotic lesions. Biopsy in tumors that are predominantly cystic as identified at CT or MR imaging, and particularly in those with fluid levels, is most likely to result in nondiagnostic results. Diagnos-

tic errors at percutaneous biopsy are unlikely to be easily corrected at open surgical biopsy.

**Acknowledgment:** Thanks to Nancy Carnes, BA, for her tireless dedication in preparing the manuscript.

#### References

1. Fraser-Hill MA, Renfrew DL, Hilsenrath PE. Percutaneous needle biopsy of musculoskeletal lesions. I. Effective accuracy and diagnostic utility. *AJR Am J Roentgenol* 1992; 158:809–812.
2. Bickels J, Jelinek JS, Shmookler BM, Neff RS, Malawer MM. Biopsy of musculoskeletal tumors: current concepts. *Clin Orthop* 1999; 368:212–219.
3. DeSantos LA, Murray JA, Ayala AG. The value of percutaneous needle biopsy in the management of primary bone tumors. *Cancer* 1979; 43:735–744.
4. Dupuy DE, Rosenberg AE, Punyaratabandu T, Tan MH, Mankin HJ. Accuracy of CT-guided needle biopsy of musculoskeletal neoplasms. *AJR Am J Roentgenol* 1998; 171:759–762.
5. Ayala AG, Ro JY, Fanning CV, Flores JP, Yasko AW. Core needle biopsy and fine-needle aspiration in the diagnosis of bone and soft-tissue lesions. *Hematol Oncol Clin North Am* 1995; 9:633–651.
6. Costa MJ, Campman SC, Davis RL, et al. Fine-needle aspiration cytology of sarcoma: retrospective review of diagnostic utility and specificity. *Diagn Cytopathol* 1996; 15:23–32.
7. Huvos AG. The importance of the open surgical biopsy in the diagnosis and treatment of bone and soft tissue tumors. *Hematol Oncol Clin North Am* 1995; 9:541–544.
8. Mankin HJ, Lange TA, Spanier SS. The hazards of biopsy in patients with malignant primary bone and soft-tissue tumors. *J Bone Joint Surg Am* 1982; 64:1121–1127.
9. Mankin HJ, Mankin CJ, Simon MA. The hazards of biopsy, revisited. *J Bone Joint Surg Am* 1996; 78:656–663.
10. Kumar RV, Rao CR, Hazarika D, Mukherjee G, Gowda BM. Aspiration biopsy cytology of primary bone lesions. *Acta Cytol* 1993; 37:83–89.
11. Kreicbergs A, Bauer HCF, Brosjo O, Lindholm J, Skoog L, Soderlund V. Cytological diagnosis of bone tumors. *J Bone Joint Surg Br* 1996; 78:258–263.
12. Layfield LJ, Glasgow BJ, Anders KH, Mirra JM. Fine needle aspiration cytology of primary bone lesions. *Acta Cytol* 1987; 31:177–184.
13. Layfield LJ, Anders KH, Glasgow BJ, Mirra JM. Fine-needle aspiration of primary soft-tissue lesions. *Arch Pathol Lab Med* 1986; 110:420–424.
14. Agarwal PK, Wahal KM. Cytopathologic study of primary tumors of bones and joints. *Acta Cytol* 1983; 27:23–27.
15. Akerman M. Fine-needle aspiration cytology of soft-tissue sarcoma: benefits and limitations. *Sarcoma* 1998; 2:155–161.
16. Miralles TG, Gosalbez F, Menendez P, Astudillo A, Torre C, Buesa J. Fine needle aspiration cytology of soft-tissue lesions. *Acta Cytol* 1986; 30:671–678.
17. Moore TM, Meyers MH, Patzakis MJ, Terry R, Harvey P Jr. Closed biopsy of musculoskeletal lesions. *J Bone Joint Surg Am* 1979; 61:375–380.
18. Oland J, Rosen A, Reif R, Sayfan J, Orda R. Cytodiagnosis of soft tissue tumors. *J Surg Oncol* 1988; 37:168–170.
19. Serpell JW, Fish SH, Fisher C, Thomas JM. The diagnosis of soft-tissue tumours. *Ann R Coll Surg Engl* 1992; 74:277–280.
20. Barth RJ, Merino MJ, Solomon D, Yang JC, Baker AR. A prospective study of the value of core needle biopsy and fine needle aspiration in the diagnosis of soft tissue masses. *Surgery* 1992; 112:536–543.
21. Zornoza J, Bernardino ME, Ordóñez NG, Thomas JL, Cohen MA. Percutaneous needle biopsy of soft-tissue tumors guided by ultrasound and computed tomography. *Skeletal Radiol* 1982; 9:33–36.
22. Ward WG, Kilpatrick S. Fine needle aspiration biopsy of primary bone tumors. *Clin Orthop* 2000; 373:80–87.
23. Skrzynski C, Biermann JS, Montag A, Simon MA. Diagnostic accuracy and charge-savings of outpatient core needle biopsy compared with open biopsy of musculoskeletal tumors. *J Bone Joint Surg Am* 1996; 78:644–649.
24. Fraser-Hill MA, Renfrew DL, Hilsenrath PE. Percutaneous needle biopsy of musculoskeletal lesions. II. Cost-effectiveness. *AJR Am J Roentgenol* 1992; 158:813–818.
25. Yao L, Nelson SD, Seeger LL, Eckardt JJ, Eilber FR. Primary musculoskeletal neoplasms: effectiveness of core-needle biopsy. *Radiology* 1999; 212:682–686.
26. Simon MA. Current concepts review: biopsy of musculoskeletal tumors. *J Bone Joint Surg Am* 1982; 64:1253–1257.
27. Akerman M, Idvall I, Rydholm A. Cytodiagnosis of soft-tissue tumors and tumor-like conditions by means of fine needle aspiration biopsy. *Arch Orthop Trauma Surg* 1980; 96:61–67.
28. Akerman M, Killander D, Rydholm A, Rooser B. Aspiration of musculoskeletal tumors for cytodiagnosis and DNA analysis. *Acta Orthop Scand* 1987; 58:523–528.
29. Jelinek JS, Murphey MD, Kransdorf MJ, Shmookler BM, Malawer MM, Hur RC. Parosteal osteosarcoma: value of MR and CT in predicting histologic grade. *Radiology* 1996; 201:837–842.
30. Anderson MW, Temple HT, Dussault RG, Kaplan PA. Compartmental anatomy: relevance to staging and biopsy of musculoskeletal tumors. *AJR Am J Roentgenol* 1999; 173:1663–1671.
31. Leffler SG, Chew FS. CT-guided percutaneous biopsy of sclerotic bone lesions: diagnostic yield and accuracy. *AJR Am J Roentgenol* 1999; 172:1389–1392.
32. Mueller PR, Biswal S, Halpern EF, Kaufman JA, Lee MJ. Interventional radiologic procedures: patient anxiety, perception of pain, understanding of procedure, and satisfaction with medication—a prospective study. *Radiology* 2000; 215:684–688.